

Successful medical management of prosthetic-valve endocarditis complicated by perivalvular abscess

Tratamento clínico de endocardite em prótese valvar complicada por abscesso para-protético

Maria do Carmo Pereira NUNES¹, Claudio Leo GELAPE², Felipe Batista Lima BARBOSA³, Luciano Ribeiro LEDUC³, Christiano Gonçalves de ARAÚJO⁴, Lucas Fabel CHALUP⁵, Marcela Ferreira NICOLIELLO⁵, Teresa Cristina Abreu FERRARI¹

RBCCV 44205-1111

Abstract

We present a case of a 44-year-old man with prosthetic aortic endocarditis complicated by a perivalvular abscess that was spontaneously drained into the left ventricular chamber. He had a history of rheumatic fever and had previously been submitted to three valve replacements because of biological prosthesis dysfunction and infective endocarditis. We briefly discuss the main features of paravalvular abscess complicating infective endocarditis.

Descriptors: Endocarditis. Heart valve prosthesis. Cardiac surgical procedures.

Resumo

O presente artigo relata o caso de um paciente do sexo masculino, 44 anos, com endocardite em prótese aórtica complicada por abscesso para-protético. Evoluiu com melhora do processo infeccioso apenas com o tratamento clínico. História prévia de doença reumática, submetido a três cirurgias cardíacas para troca valvar por disfunção de prótese e endocardite prévia. Neste relato de caso, discutiremos as características principais do abscesso para-protético como complicação de endocardite.

Descritores: Endocardite. Próteses valvulares cardíacas. Procedimentos cirúrgicos cardíacos.

INTRODUCTION

We present a case of a 44-year-old man with prosthetic aortic endocarditis complicated by a perivalvular abscess that was spontaneously drained into the left ventricular chamber. He had a history of rheumatic fever and had previously been submitted to 3 valve replacements because of biological prosthesis dysfunction and infective endocarditis. We briefly discuss the main features of paravalvular abscess complicating infective endocarditis.

Myocardial abscess formation is a severe complication

of infective endocarditis (IE) that is associated with high mortality. The aortic valve and its adjacent ring are more susceptible to abscess formation and complications of paravalvular extension of the infection than the mitral one. Prosthetic-valve endocarditis (PVE) is also more frequently associated with these types of complications than the native valves [1,2].

We report a case of prosthetic aortic endocarditis complicated by paravalvular extension of the infection with an abscess formation that was spontaneously drained into the left ventricular chamber.

1. MD, PhD. Federal University of Minas Gerais – School of Medicine – Department of Internal Medicine.
2. MD, PhD. Federal University of Minas Gerais – University Hospital – Division of Cardiology and Cardiovascular Surgery.
3. MD. Federal University of Minas Gerais – School of Medicine.
4. MD. Federal University of Minas Gerais – University Hospital – Division of Cardiology and Cardiovascular Surgery.
5. Federal University of Minas Gerais – School of Medicine.

Work done at 1-Federal University of Minas Gerais - School of Medicine - Department of Internal Medicine 2- Federal University of Minas Gerais - University Hospital - Division of Cardiology and

Cardiovascular Surgery 3- Federal University of Minas Gerais - School of Medicine.

Correspondence address:

Maria do Carmo Pereira Nunes, MD, PhD Universidade Federal de Minas Gerais, Faculdade de Medicina, Departamento de Clínica Médica, Av. Prof. Alfredo Balena, 190 - Belo Horizonte, MG, Brazil – ZIP Code: 30130-100.

E-mail: mcarmo@waymail.com.br

Article received on March 17th, 2009

Article accepted on June 29th, 2009

CASE REPORT

A 44-year-old man was admitted to the University Hospital, Federal University of Minas Gerais, Belo Horizonte, Brazil complaining of fever, anorexia and shortness of breath for the past 3 weeks. He had a history of rheumatic fever and had previously been submitted to three valve replacements. In 1982, the native aortic valve was replaced with a biological prosthesis due to aortic insufficiency. Seven years later, this prosthesis was replaced with a mechanical one because of its dysfunction. The last cardiac surgery, in 2002, was performed because of IE of the aortic prosthesis.

At that time, the mitral valve was also replaced due to rheumatic process causing severe valve dysfunction. Therefore, at the time of the present admission, the patient had mechanical valves at both aortic and mitral positions. Physical examination revealed a normal valve click sound, hepatosplenomegaly and a temperature of 38.4°C. There were signs heart failure and no murmurs. No peripheral stigmata of IE were noticed.

Laboratory investigations showed hemoglobin 6.3 g/dL, white blood cell count 6,220/ μ L, and C-reactive protein 64 mg/L (normal value < 5 mg/L). Serum chemistry and urine analysis were normal. Blood cultures were negative for aerobic bacteria and fungi. Anaerobic blood cultures were not obtained. The electrocardiogram (ECG) was unremarkable. A transthoracic echocardiography (TTE) demonstrated mild aortic regurgitation without any evidence of vegetation, and diffuse hypokinesis (ejection fraction 48%).

One week later, as the patient continued to present daily fever, a transesophageal echocardiography (TEE) was performed and revealed a mobile vegetation attached to the prosthetic mitral valve ring, and an echolucent area, suggestive of an abscess cavity at the mitral-aortic intervalvular fibrosa (Figure 1).

Therapy with vancomycin, gentamycin and rifampin was started, and the patient was taken to the operation room. The prostheses as well as the intervalvular fibrosa area were carefully examined. During the transvalvar aortic and transvalvar septal explorations, a cavity that communicates with the outflow tract of the left ventricle was found. It was located at the same site of the TEE abscess imaging suggesting spontaneous drainage of the abscess with an aneurysm formation. Moreover, neither valve dehiscence nor instability of the prostheses was noticed. Considering these findings along with the high morbidity and mortality associated with a fourth valve replacement, this procedure was not performed.

The patient presented a progressive improvement and became afebrile. Six weeks after the beginning of the antibiotics, a new TEE strongly suggested that the mitral-aortic intervalvular fibrosa abscess had evolved into an aneurysm (Figure 2).

The patient was discharged from the hospital taking penicillin G benzathine (1.2 million units every 28 days) and erythromycin (2 g/daily), and was followed up closely.

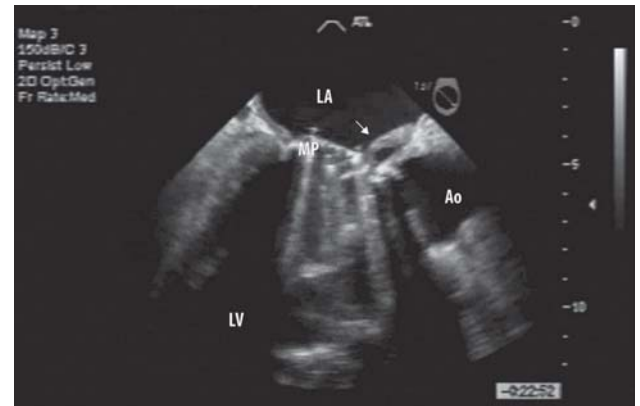


Fig. 1 - Transesophageal long-axis view showing a small abscess at the mitral-aortic intervalvular fibrosa. Abscess is the abnormal echolucent area within the intervalvular fibrosa

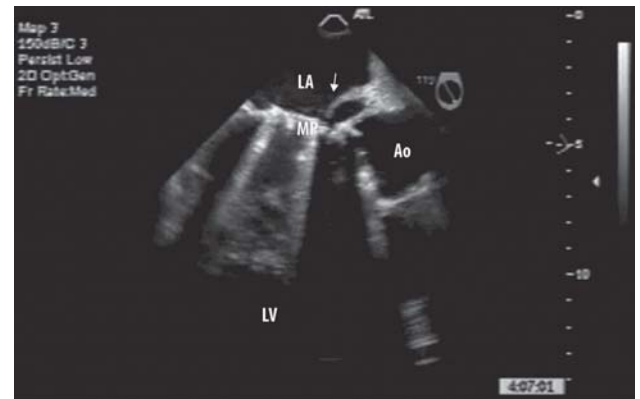


Fig. 2 - Transesophageal echocardiogram showing an abscess evolving into an aneurysm in the mitral-aortic intervalvular fibrosa

During the next 6 weeks, he noticed some isolated episodes of fever that became progressively less frequent until its complete disappearance. A new TEE, performed 2 months after the patient had been discharged from the hospital, showed an aneurysm in the intervalvular fibrosa area that communicates to the left ventricular chamber through an outflow tract, which was best visualized by the Color-flow Doppler imaging. The antibiotics were discontinued. Thirty months later, he remains well with no recurrence.

DISCUSSION

Periannular extension of the infection in IE is a serious and relatively common complication, which is associated

with high mortality rate [3]. It appears to be caused by bacterial invasion and destruction of the local tissue, and usually leads to abscess formation. Abscess-related lesions are more frequent when the infecting organism is *Staphylococcus aureus*. Periannular lesions occasionally rupture into the adjacent cardiac chambers causing aortocavitary fistulae, and hemodynamic instability. Echocardiography, particularly the TEE, is of utmost value in the diagnosis and evaluation of such lesions [3,4]. Patients with periannular complications of IE constitute a well-defined group of individuals in whom surgery is necessary, and there is a wide range of possible surgical procedures to treat them [5].

Early surgical intervention is warranted when there is echocardiographic evidence of paravalvular abscess [5]. Surgeons have long focused on treating IE and its major complication, i.e. the abscesses, especially those located in the aortic ring, using different surgical alternatives [6]. Our patient underwent careful surgical exploration of the mitral and aortic prostheses, and intervalvular fibrosa area. During the surgical procedure, a cavity that communicates with the outflow tract of left ventricle was found. It was located at the same site of the TEE abscess imaging, which suggested spontaneous drainage of the abscess with aneurysm formation. As surgical inspection disclosed neither instability nor dysfunction of the prostheses, the surgical team decided not to perform a new valve replacement because of the high risk of such procedure in the present case.

The appropriate operative procedures for treating IE are still controversial. Although the outcome was greatly improved with ample resection of the infected tissue and laborious reconstructions [6,7], the good evolution of our patient was probably due to the spontaneous drainage of the abscess. It is important to emphasize that clinical approach does not represent an alternative to surgery when it is feasible, but is merely the best opportunity for patients too ill to tolerate a re-intervention [8].

A misinterpretation of the echocardiographic imaging could have been an explanation for the favorable outcome of our patient; however, the evolution of such imaging in the repeated examinations along with the surgical findings led us to conclude that it was an abscess which evolved into an aneurysm.

In synthesis, we present an uncommon case of paravalvular abscess complicating PVE that respond to a combined course of intravenous and oral antibiotics administered for a long period of time, and experienced clinical and echocardiographic resolution of the infection.

REFERENCES

1. Wang A, Athan E, Pappas PA, Fowler VG Jr, Olaison L, Paré C, et al; International Collaboration on Endocarditis-Prospective Cohort Study Investigators. Contemporary clinical profile and outcome of prosthetic valve endocarditis. *JAMA*. 2007;297(12):1354-61.
2. Habib G, Thuny F, Avierinos JF. Prosthetic valve endocarditis: current approach and therapeutic options. *Prog Cardiovasc Dis*. 2008;50(4):274-81.
3. Daniel WG, Mügge A, Martin RP, Lindert O, Hausmann D, Nonnast-Daniel B, et al. Improvement in the diagnosis of abscesses associated with endocarditis by transesophageal echocardiography. *N Engl J Med*. 1991;324(12):795-800.
4. Hill EE, Herijgers P, Claus P, Vanderschueren S, Peetermans WE, Herregods M C. Abscess in infective endocarditis: the value of transesophageal echocardiography and outcome: a 5-year study. *Am Heart J*. 2007;154(5):923-8.
5. American College of Cardiology; American Heart Association Task Force on Practice Guidelines (Writing Committee to Revise the 1998 guidelines for the management of patients with valvular heart disease); Society of Cardiovascular Anesthesiologists, Bonow RO, Carabello BA, Chatterjee K, de Leon AC Jr, Faxon DP, Freed MD, et al. ACC/AHA 2006 guidelines for the management of patients with valvular heart disease: a report of the American College of Cardiology/American Heart Association Task Force on Practice Guidelines (writing Committee to Revise the 1998 guidelines for the management of patients with valvular heart disease) developed in collaboration with the Society of Cardiovascular Anesthesiologists endorsed by the Society for Cardiovascular Angiography and Interventions and the Society of Thoracic Surgeons. *J Am Coll Cardiol*. 2006;48(3):e1-148.
6. Arnoni AS, Arnoni RT, Paulista PP, Martinez VE, Almeida AF, Abdulmassih Neto C, et al. Surgery for aortic valve endocarditis: treatment options for aortic abscess. *Arq Bras Cardiol*. 2008;91(2):65-9.
7. Arnoni AS, Falcão HCB, Oliveira JB, Dinkhuysen JJ, Abdulmassih Neto C, Chacur P, et al. Tratamento cirúrgico do abscesso aórtico com descontinuidade ventrículo esquerdo-aorta em endocardite infecciosa. *Rev Bras Cir Cardiovasc*. 1987;2(1):53-60.
8. Anguera I, Miro JM, San Roman JA, de Alarcon A, Anguita M, Almirante B, et al; Aorto-Cavitary Fistula in Endocarditis Working Group. Periannular complications in infective endocarditis involving prosthetic aortic valves. *Am J Cardiol*. 2006;98(9):1261-8.