

# Heart transplantation in primary amyloidosis

## *Transplante cardíaco em amiloidose primária*

José Francisco BAUMGRATZ<sup>1</sup>, José Henrique Andrade VILA<sup>2</sup>, Claudia Jesus GUILHEN<sup>3</sup>, Luciana da FONSECA<sup>4</sup>, Weverton Ferreira LEITE<sup>3</sup>, Carlos D'ANDRETTA<sup>5</sup>, Américo TÂNGARI JUNIOR<sup>3</sup>, José Pedro da SILVA<sup>6</sup>

RBCCV 44205-1109

### **Abstract**

Cardiac amyloidosis is a disease that highly compromises the survival expectancy after the beginning of the symptomatic phase, usually with sudden death as the final event. The aggression to other organs, although, can make heart transplantation a disputable form of treatment taking into consideration the shortage of organ donors. The aim is to report the evolution with a survival of seven years after heart transplantation and in fair condition of a patient with amyloidosis. One year after the heart transplantation, the patient was referred to renal transplantation also in consequence of the disease aggression. The patient evolution was favorable compared to three other patients also from our service, who died early after the diagnosis. Even considering the multi-systemic nature of amyloidosis, we can accept that in selected patients the heart transplantation is justified, taking into account the very ill prognosis of the disease.

**Descriptors:** Amyloidosis. Heart transplantation. Cardiomyopathies/surgery.

### **Resumo**

A amiloidose cardíaca é doença altamente limitante da sobrevida, por morte súbita na maioria dos pacientes. Pela agressão contra outros órgãos, particularmente rins e sistema nervoso central, o transplante cardíaco tem sido opção questionável, face à escassez de órgãos. O objetivo é relatar a evolução, com sobrevivência de 7 anos, da paciente após transplante cardíaco por amiloidose, em boas condições. Um ano após o transplante cardíaco, houve indicação de transplante renal, também pela agressão da doença. Esta paciente contrasta com outros três pacientes de nosso serviço que foram a óbito, ainda na fase de avaliação. Apesar de sua natureza multisistêmica, a amiloidose cardíaca pode, em pacientes selecionados, justificar o transplante cardíaco, pela gravidade do seu potencial evolutivo após o início dos sintomas.

**Descritores:** Amiloidose. Transplante de coração. Cardiomiopatias/cirurgia.

1. Cardiovascular surgeon - Assistant of Dr. José Pedro da Silva group at Hospital Beneficência Portuguesa, São Paulo, Brazil.
2. Postgraduate in Medicine at UNIFESP- Chief of ICU of Dr. José Pedro da Silva group at Hospital Beneficência Portuguesa, São Paulo, Brazil.
3. Assistant of Cardiology of Dr. José Pedro da Silva group at Hospital Beneficência Portuguesa, São Paulo, Brazil.
4. Postgraduate in Medicine at UNIFESP- Surgeon assistant of Dr. José Pedro da Silva group at Hospital Beneficência Portuguesa, São Paulo, Brazil
5. Specialist in Pathologic Anatomy- Pathology Anatomy team at Hospital Beneficência Portuguesa, São Paulo, Brazil.
6. PhD. in Cardiovascular Surgery - FMUSP - Chief of Cardiovascular Group at Hospital Beneficência Portuguesa, São Paulo, Brazil.

Work performed at Hospital São Joaquim da Real e Benemerita Associação Portuguesa de Beneficência – São Paulo, SP, Brazil.

### Correspondence address:

José Henrique Andrade Vila. Rua Maestro Cardim, 1041– Paraíso – São Paulo, SP, Brazil. ZIP Code: 01323-001.  
E-mail: drvila@terra.com.br

Article received on January 27<sup>th</sup>, 2009  
Article approved on June 26<sup>th</sup>, 2009

INTRODUCTION

Amyloidosis in its systemic primary form presents frequent cardiac aggression, as well as attacking the kidneys, liver, intestines and other organs; and due to the myocardial aggression, important limitation of survival in our experience ; and in the literature review is very meaningful [1,2].

Pereira et al. [3], in a national issue, have already pointed out the very high rate of mortality when the diastolic cardiac insufficiency in its clinical form is installed. Out of eight patients with cardiac amyloidosis studied, six patients presented cardiac insufficiency, three patients died in less than three months, which is in accordance with our previous experience of three cases in which all died prior to the cardiac transplantation, still in the evaluation stage (Table 1).

Cardiac transplantation is considered today a method of undeniable importance in the treatment of terminal cardiac insufficiency, which faces, however, the lack of organ availability, resulting in a decrease in the number of operations in the First World countries. Due to violence control measures and mainly of vehicular accident prevention through increasingly more strict traffic laws in the Western world, it is believed that a deficiency in the amount of organs, especially of hearts, will be gradual in the next few years. This fact makes relevant the selection of receptors, having preference for cardiac transplantation those patients that present a positive potential of evolution [4-8]. It was included in the aforementioned literature the simultaneous transplantation of heart and liver, also affected by the disease, which could enhance the evolution prognostic of amyloidosis.

The cardiac transplantation in patients holding systemic amyloidosis is still an issue as a result of the systemic characteristics of the disease and of the relative unpredictability of its natural history, which could compromise the long-term survival of the receptors and, therefore, make the initial procedure innocuous. The positive evolution of the present case, operated on September 24, 2001; and the excellent clinical evolution of the patient particularly after a kidney transplantation performed on April 8, 2002, allow us to evaluate that, in selected cases, this could be a reasonable procedure.

Nevertheless, reports in literature reveal clearly the possibility of recurrence of the disease, either in the heart or other organs [7-9].

Likewise, it is also extremely important the caution in the diagnostic, particularly for the exclusion of another type of restrictive cardiomyopathy, which is the constrictive pericarditis, especially in unusual manifestations [10].

Table 1. Cases with death in previous experience of the group

Case	Gender	Age (years)	Type	Death	Time after inclusion in the list(d)
1	M	54	?	Sudden	1
2	M	47	AL	Aggravation of symptoms.	53
3	F	55	AL	Sudden	97

CASE REPORT

Patient, V.A.C., 49 years-old, was referred to our service, presenting heart dysfunction class III/IV (NYHA). The Doppler-echocardiogram performed revealed, normal size of the right and left ventricles; ejection fraction of the left ventricle was 53%, with probable biventricular amyloid infiltration, including the ventricular septum, interfering with the myocardial complacence, compatible with the amyloid deposit disease; important tricuspid insufficiency and minimal pericardial effusion (Figure 1). This finding was confirmed by cardiac magnetic resonance that evidenced compromising of the biventricular systolic function probably as a result of the deposit disease.

On August 3, 2001, it was performed a myocardial biopsy that revealed cardiac amyloidosis. Due to the unfavorable evolution, characteristic of the primary cardiac amyloidosis, it was indicated the heart transplantation (Figures 2 and 3).

After performing protocol for heart transplantation (normal laboratory examination, negative criss-cross match, pulmonary gradient of 6 mmHg), the patient was accepted for the heart transplantation procedure. On August 31, 2001, she suffered cardiopulmonary arrest, being performed the cardiopulmonary resuscitation maneuvers (CPR) successfully and given priority for heart transplantation.

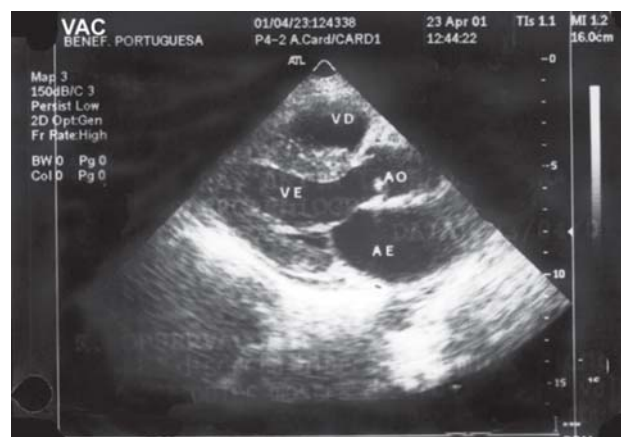

Fig. 1 – Echocardiogram evidenced deposit disease (observe the ventricular septum)

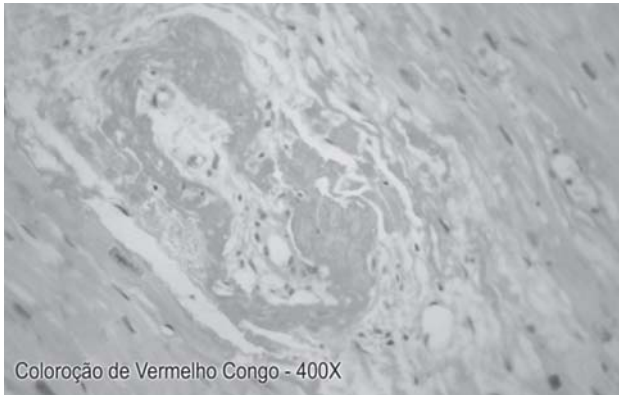


Fig. 2 - Endomyocardic Biopsy displaying amyloidosis

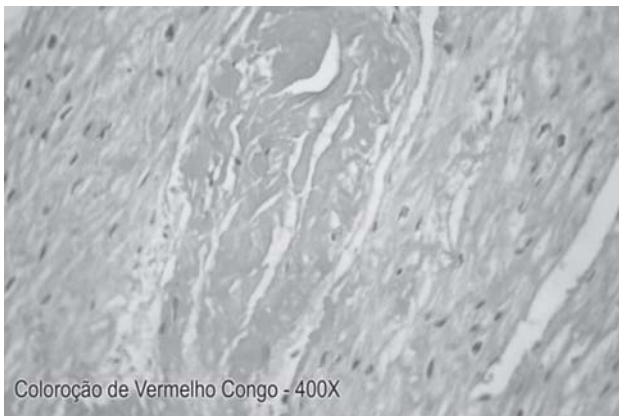


Fig. 3 - Endomyocardic Biopsy displaying amyloidosis

On September 24, 2001, it was performed orthotopic heart transplantation, without interurrences, however, being kept under peritoneal dialysis between September 19 and November 16, 2001.

The immunosuppression applied was oral cyclosporine 70 mg, every 12 hours, and mofetil micofenofate 500 mg, every 12 hours, applying 1 g of metylprednisolone at the end of the heart transplantation.

The myocardial biopsies performed on October 24, November 9 and December 16, 2001 revealed zero degree. The renal function kept progressively declining, being confirmed by renal biopsy performed on October 31, 2001, the presence of renal amyloidosis, being indicated for transplantation by the nephrology group.

The evolution after the renal transplantation, which was performed on April 8, 2002; was positive when the immunosuppression threefold scheme was applied, adding prednisone in low doses of 0.1 mg/kg to cyclosporine and to mofetil micofenolate.

After 11 months from the cardiac transplantation, the patient was interned due to tachycardia and fever to be confirmed. It was performed a Doppler-echocardiogram that revealed left ventricle with normal function, size and segment contraction, mild tricuspid insufficiency, normal aorta and right chambers, with no further abnormalities. The cardiac biopsy demonstrated zero degree, eliminating rejection from the graft, maintaining the same scheme of immunosuppression.

It was diagnosed bronchopneumonia by the thorax X-Ray and clinical examination, being performed the adequate therapy.

No biopsy performed revealed any evidence of amyloidosis that could imply aggression rejection to the implanted organ (Figure 4).

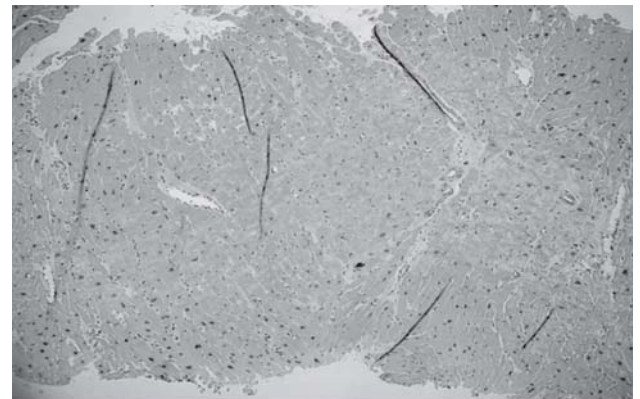


Fig. 4 - Endomyocardic Biopsy with 5 year - evolution, displaying absence of infiltrated amyloid

## DISCUSSION

In the literature review, there is an insufficiency of series with a significant number of cases that could establish a reliable pattern for the dubious and difficult referral of transplantation for cardiac amyloidosis. The larger series found was at the Harefield Hospital, England, in which, out of 10 operated cases, only one patient achieved late survival [9]. All other issues on the subject refer to isolate cases, however, there are reports that state the possibility of treatment for the amyloidosis disease as a real clinical alternative, which brings new expectations for these patients [1,3-8].

In the present case there was also found renal aggravation and we were able to preserve the kidneys function at acceptable levels, reducing the cyclosporine dosage. Nearly a year later, a renal transplantation was required; however, it is worth mentioning the fact that no cardiac biopsy suggested any degree of cardiac rejection,

even considering the immunosupresor scheme attenuated by the difficult clinical characteristics that the patient presented.

Other three cases of cardiac amyloidosis evaluated at our service, died right after the diagnosis, still at the stage of diagnostic investigation for heart transplantation.

In the literature, we find different opinions regarding the opportunity for heart transplantation as a consequence of cardiac amyloidosis, however, due to the fair 4-year evolution of our patient, we could assume that young patients suffering limited amyloidosis aggression to the heart (or heart and kidneys) can be candidates for heart transplantation until there are larger series of patients that could definitely clarify this difficult issue.

Also, favorable to this policy, there is the fact that the clinical therapy for this deposit disease has been attempted with reasonably initial success [2,6,9].

#### REFERENCES

1. Hosenpud JD, DeMarco T, Frazier OH, Griffith BP, Uretsky BF, Menkis AH, et al. Progression of systemic disease an reduced long-term survival in patients with cardiac amyloidosis undergoing heart transplantation. Follow-up results of a multicenter survey. *Circulation*. 1991;84(5 Suppl):III338-43.
2. Lebrazi H, Hachulla E, Saile R. Treatments for amyloidosis beyond symptomatic care. *Rev Med Interne*. 2000;21(3):247-55.
3. Pereira Barreto AC, Bellotti G. Cardiomiopatias não inflamatórias. *Rev Soc Cardiol Estado de São Paulo*. 1996;6(4):417-26.
4. Alloni A, Pellegrini C, Ragni T, Goggi C, D'Armini AM, Rinaldi M, et al. Heart transplantation in patients with amyloidosis: single-center experience. *Transplant Proc*. 2004;36(3):643-4.
5. Arpesella G, Chiappini B, Marinelli G, Mikus PM, Dozza F, Pierangeli A, et al. Combined heart and liver transplantation for familial amyloidotic polyneuropathy. *J Thorac Cardiovasc Surg*. 2003;125(5):1165-6.
6. Nardo B, Beltempo P, Bertelli R, Montalti R, Vivarelli M, Cescon M, et al. Combined heart and liver transplantation in four adults with familial amyloidosis: experience of a single center. *Transplant Proc*. 2004;36(3):645-7.
7. Dubrey S, Simms RW, Skinner M, Falk RH. Recurrence of primary (AL) amyloidosis in a transplanted heart with four-year survival. *Am J Cardiol*. 1995;76(10):739-41.
8. Ocel JJ, Edwards WD, Tazelaar HD, Petrovic LM, Edwards BS, Kamath PS. Heart and liver disease in 32 patients undergoing biopsy of both organs, with implications for heart or liver transplantation. *Mayo Clin Proc*. 2004;79(4):492-501.
9. Dubrey SW, Burke MM, Hawkins PN, Banner NR. Cardiac transplantation for amyloid heart disease: the United Kingdom experience. *J Heart Lung Transplant*. 2004;23(10):1142-53.
10. Godoy MF, Francischi FB, Pavarino PR, Oliveira MAB, Soares MJF, Braile DM, et al. Forma inusitada de pericardite crônica constrictiva idiopática. *Rev Bras Cir Cardiovasc*. 2007;22(1):1-6.