

Outcomes of aortic coarctation surgical treatment in adults

Resultados do tratamento cirúrgico da coarctação de aorta em adultos

Marcelo Biscegli JATENE¹, Décio Cavalet Soares ABUCHAIM², José de Lima OLIVEIRA JUNIOR³, Arlindo RISO⁴, Carla TANAMATI⁵, Nana MIURA⁶, Antonio Augusto LOPES⁷, Miguel L. BARBERO-MARCIAL⁸

RBCCV 44205-1099

Abstract

Objective: The aim of this study is to describe our experience in aortic coarctation surgery in adult patients by assessing the immediate and mid-term outcomes.

Methods: From January 1997 to March 2000, 50 consecutive adult patients underwent surgery for correction of aortic coarctation, through left lateral thoracotomy. Of these, forty two (84%) patients presented high blood pressure, with mean systolic arterial pressure of 170.56 mmHg (125-220 mmHg). The mean of pressure gradient in the coarctation area was 51.4 mmHg (18-123 mmHg). Other associated surgical cardiovascular diseases were not treated in the same operative act, except in two cases of patent ductus arteriosus (PDA). Three different techniques were used: aortic coarctation resection with end-to-end anastomosis was performed in 20 (40%) patients, coarctation enlargement with bovine pericardial patch was performed in 22 (44%)

patients and synthetic tube interposition was performed in eight (16%) patients.

Results: Operative morbidity was low; there was one case of bleeding who required reoperation. The most common immediate postoperative event was high blood pressure (98%), but it was easily controlled by intravenous drugs. There was no hospital death. Mean residual pressure gradient was 18.7 (8-33 mmHg). Patients were discharged in 9.5 days (5-30). Postoperative follow-up mean was 46.8 months (1-145 months) in 45 (91.8%) patients. Forty one (91.1%) of these followed-up patients had normal blood pressure, whereas 75.6% of them without drugs intake. 93.3% of these followed-up patients were asymptomatic. Four of them required further surgical operation, one needed a pacemaker implant, other two patients needed a cardiac valve replacement and one had endocarditis. There was one related death due to sepsis secondary to endocarditis.

1. Associated Professor.
2. Master's Degree.
3. Master's Degree.
4. Master's Degree.
5. Master's Degree.
6. Master's Degree.
7. Associated Professor.
8. Associated Professor.

da Faculdade de Medicina da Universidade de São Paulo, São Paulo, SP, Brazil.

Correspondence address:
Marcelo Biscegli Jatene - Av. Dr. Enéas de Carvalho Aguiar, 44 - São Paulo, SP, Brazil - ZIP Code: 05403-900.
E-mail: mbjatene@uol.com.br

Conclusion: Surgical treatment of aortic coarctation, even in adult patients, is an efficient therapeutic choice, regardless of the applied surgical technique, with low morbidity and mortality. It reduces efficiently the arterial pressure levels in both immediate and mid-term follow-up.

Descriptors: Aortic coarctation/surgery. Aorta/surgery. Heart defects, congenital. Adult.

Resumo

Objetivo: Reportar a experiência no tratamento cirúrgico da coarctação da aorta (CoAo) em pacientes adultos, avaliando os resultados imediatos e a médio prazo.

Métodos: Entre janeiro de 1987 e março de 2000, 50 pacientes consecutivos adultos foram submetidos a tratamento cirúrgico da coarctação de aorta, por toracotomia lateral esquerda. Destes, 42 (84%) eram hipertensos, com pressão arterial sistólica média de 170,6 mmHg (125-220 mmHg). O gradiente médio no local da coarctação era de 51,4 mmHg (18-123 mmHg). A abordagem de doenças cardiovasculares associadas não foi realizada no mesmo tempo cirúrgico, com exceção de dois casos de persistência do canal arterial (PCA). Ressecção da CoAo e anastomose término-

terminal foi realizada em 20 (40%) pacientes, ampliação da área de CoAo com retalho de pericárdio bovino em 22 (44%) e interposição de um tubo sintético em oito (16%).

Resultados: A morbidade operatória foi baixa, ocorrendo apenas uma reoperação por sangramento; a ocorrência mais frequente nas primeiras horas de pós-operatório foi hipertensão, observada em 98% dos pacientes, controlada com medicamentos endovenosos. Não houve óbito hospitalar. O gradiente residual médio foi de 18,7 mmHg (8-33 mmHg). O tempo médio de internação hospitalar foi de 9,5 dias (5-30 dias). O tempo médio de seguimento foi de 46,8 meses (1-145 meses) em 45 (91,8%) pacientes; destes, 41 (91,1%) encontravam-se normotensos, sendo que 75,6% sem medicamentos. Em 93,3% dos pacientes, não ocorreram sintomas de qualquer natureza. Quatro pacientes foram reoperados neste período (um para implante de marca-passo definitivo, dois para troca valvar, e outro por endocardite), ocorrendo um óbito tardio por endocardite e sepse.

Conclusão: O tratamento cirúrgico da CoAo, mesmo em pacientes adultos, impõe-se como método terapêutico eficaz, nesta série, independentemente da técnica cirúrgica utilizada, com baixa morbidade e mortalidade, e sobretudo reduzindo os níveis pressóricos a curto e médio prazos.

Descritores: Coarctação aórtica/cirurgia. Aorta/cirurgia. Cardiopatias congênicas. Adulto.

INTRODUCTION

The presence of aortic coarctation not submitted to surgical correction in adult patients leads to the frequent occurrence of high blood pressure (HBP) in the upper limbs, as well as presenting greater risk of several clinical symptoms. Problems such as acute myocardial infarction, intracranial hemorrhage, aortic rupture and cardiac insufficiency may manifest at various moments, in association with HBP, which could lead to increase mortality, due to the possibility of the occurrence of any of the problems previously mentioned. [1,2].

In many patients, the aortic coarctation presents asymptomatic evolution, performing the diagnosis from the investigation initiated after detecting HBP. In almost all the cases, there is an exuberant collateral circulation consisting of dilated intercostal arteries, internal thoracic arteries or branches of arteries near the aortic coarctation.

Perfusion from the distal aorta to the aortic coarctation occurs, generating sufficient flow to satisfactorily perfuse the corresponding organs and tissues, concealing symptoms and complicating early diagnosis. [2,3].

The ideal time for surgical referral in aortic coarctation cases, following the established diagnosis, is variable. However, according to general consensus, the aortic coarctation must be corrected in the neonatal period or childhood, in order to avoid the sequels of late treatment,

especially those related to hypertension with long-term evolution [4-6].

Several surgical techniques have been used in the correction of aortic coarctation in adults, such as resection and performance of end-to-end anastomosis, interposition of synthetic tubes or enlargement of the coarctate zone with varied patches [7-14].

Our experience with this type of disease detected in patients aged over 18 years, including preoperative clinical aspects, correction techniques and, immediate and long-term postoperative evolution will be discussed next.

METHODS

From January 1997 to March 2000, 50 consecutive patients aged over 18 years with aortic coarctation underwent surgery at the Heart Institute of the Clinics Hospital -University of São Paulo. The numeric variables are presented as mean and standard deviation.

The patients age ranged from 18 to 59 years (mean 25.4 years), of whom 36 (72%) were male patients. The aortic coarctation was located in the descending aorta after the emergence of the left subclavian artery in all cases, being excluded from this study those presenting stenosis or coarctation of aortic arch or abdominal aorta. SH was present in 42 (84%) cases, with mean systolic pressure of 170.5 mmHg (125 to 220 mmHg) and mean diastolic pressure

of 100.1 mmHg (60 to 140 mmHg), measured in the upper limbs.

Twenty-five (50%) patients presented symptoms of a small extent (myocardial insufficiency I and II, according to the New York Heart Association); 19 (38%) were asymptomatic and 6 (12%) presented more intense symptoms (myocardial insufficiency III and IV), characterized predominantly by dyspnea to minimal efforts, as well as symptoms related to HBP, such as headache and dizziness. Two (4%) patients presented symptoms of preoperative hypertensive emergence, of which one case was of acute pulmonary edema and the other of hypertensive encephalopathy, both with positive evolution, with controlled HBP by specific medication and regression of symptoms.

Two (4%) patients who presented symptoms of congestive cardiac insufficiency by valvulopathy, moderate mitral insufficiency in one patient and moderate aortic stenosis with aortic transvalvar gradient of 58 mmHg in another, performed the aortic coarctation diagnosis during the valvar disease examination and underwent valvulopathy correction prior to the aortic coarctation correction.

In 13 (26%) patients, there were other associated heart diseases, of whom 8 (16%) presented valvar disease and 5 (10%) presented congenital heart disease. The diagnoses of the associated lesions are exposed in Table 1.

After the clinical suspicion of aortic coarctation, all patients underwent ecocardiographic evaluation that confirmed the clinical diagnostic of aortic coarctation, as well as detecting hypertrophy of the left ventricle (LV) in 33 (66%) patients and moderate dysfunction of LV in 5 (10%). Complementary diagnosis by angiography was performed in 34 (68%) patients and magnetic nuclear resonance (MNR) in 10 (20%) patients. The mean systolic gradient in the aortic coarctation region was 58.2 mmHg (28 to 123 mmHg).

Table 1. Associated cardiopathies

Cardiopathy	N (%)
Mitral insufficiency	3 (6%)
Mild	1 (2%)
Moderate	2 (4%)
Aortic insufficiency	3 (6%)
Moderate (1 case of bivalved valve)	2 (4%)
Severe	1 (2%)
Ventricular septal defect	3 (6%)
Aortic stenosis (gradient LV/Ao – 47mmHg) (1 case of bivalved valve)	2 (4%)
Persistent ductus arteriosus	2 (4%)

LV – left ventricle; Ao – aorta; mmHg - millimeters of mercury

Surgical technique

All patients underwent surgical treatment by left lateral-posterior thoracotomy; the approach was performed through the 4th left intercostal space, with selective intubation of the lungs. A careful thoracic opening by dissection and isolation of the aorta and coarctate area were performed.

Different correction techniques were used, varying according to the intraoperative aspect or the surgeon's preference for some technique of choice. In the patients in whom the correction was performed using synthetic tubes, in 5 (10%) it was performed the interposition of the tube replacing the coarctate aorta segment by end-to-end anastomosis with the proximal and distal stumps of the aorta; performing the proximal anastomosis with the subclavian artery and the distal anastomosis with the descending aorta, after the aortic coarctation.

The numeric variables are presented as mean and standard deviation. The preoperative and postoperative variables were compared by the Student's t test for analogous and non-analogous values and by the analysis of double-factor variance. Statistical significance was considered for value of $p < 0.05$. The variables behavior throughout time was estimated by the regression model proposed by Blackstone [15].

RESULTS

There was no hospital mortality. The surgical treatment consisted of isolated correction of the aortic coarctation in all cases, except for two patients, in whom it was performed section and suture of the patent arterial channel, as part of the surgical technique for isolation of the aorta, in order to facilitate its mobilization.

In the immediate postoperative period (IPO), HBP was observed in 49 (98%) patients, in need of specific medication (sodium nitroprusside in the first hours and association of beta-blocking agents or inhibitors of the conversion enzyme. Temporary low cardiac output was observed in two (4%) cases, with resolution in both until the second day of postoperative; in two (4%) patients it was detected the presence of arrhythmias, being atrial fibrillation (AF) in one and non-sustained ventricular tachycardia in another, with positive resolution after hydro-electrolytic control and medication with Amiodarone and endovenous Xylocaine, respectively. One patient required reoperation due to bleeding in order to review the hemostasia, with positive evolution.

Forty-five (91.8%) patients were evaluated between 1 to 145 months (M=46.8). One late death was observed within three months of postoperative, by sepsis due to bacterial endocarditis in aortic valve; three patients required to

undergo new surgical interventions, whereas one case for permanent pacemaker implantation, one case for aortic valve replacement and another for mitral valve replacement.

Echocardiographic evaluation revealed reduction of the mean gradient by the aortic coarctation area, reducing from 58.2 mmHg to 21.4 mmHg. The results of the preoperative and postoperative gradients in the different techniques used are exposed in Figure 1.

In the evaluation of the gradient by the aortic coarctation area, in all patients, significant reduction in the postoperative period was observed, compared to the preoperative period, as displayed in Figure 2. When comparing the surgical techniques of aortic coarctation correction (bovine pericardium versus patch, resection and end-to-end anastomosis), significant reduction of the gradient in the postoperative period was observed, compared to the preoperative period, with both techniques, however; comparing both techniques with one another, the preoperative and postoperative gradients with the different techniques were similar, as well as similar to one another (Figure 3).

After the reduction of the postoperative gradients, during the mid-term evolution, it was observed the maintenance of the mean gradients measured in different moments of the postoperative period (represented by the dots in the dispersion diagram), as displayed in Figure 4.

Considering the 45 patients followed-up during the postoperative evolution, regarding the arterial pressure, it was observed the reduction of the systolic pressure levels, with statistical significance between the preoperative and postoperative periods, as shown in Figure 5.

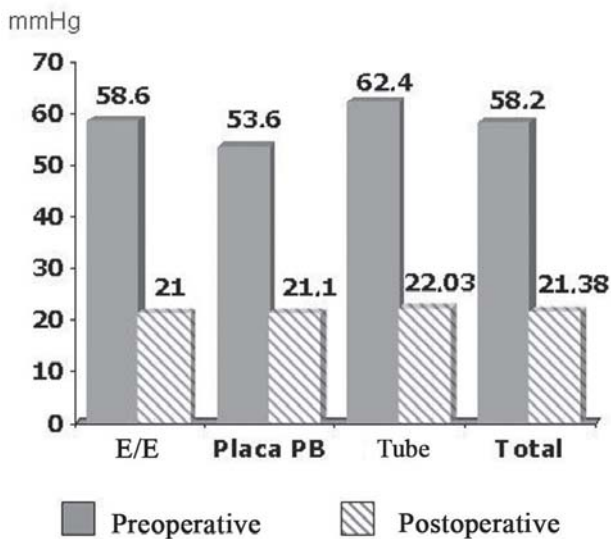


Fig. 1 – Preoperative and Postoperative gradients according to the surgical technique applied. E/E = end-to-end; BP = bovine pericardium

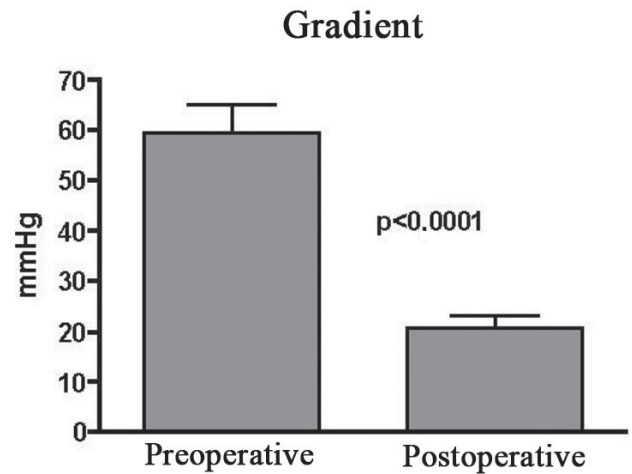


Fig. 2 – Preoperative and Postoperative gradients

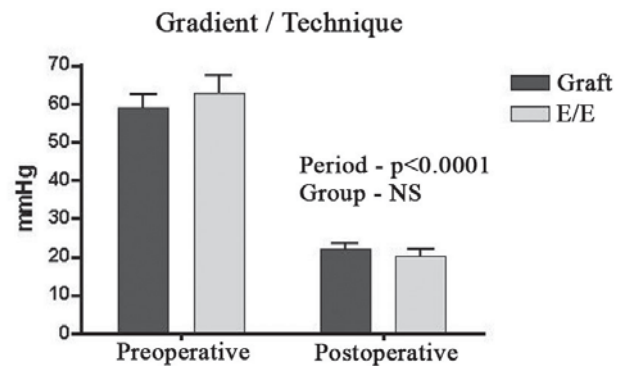


Fig. 3 - Preoperative and Postoperative gradients according to the surgical technique applied. E/E = end-to-end; mmHg = millimeters of mercury.

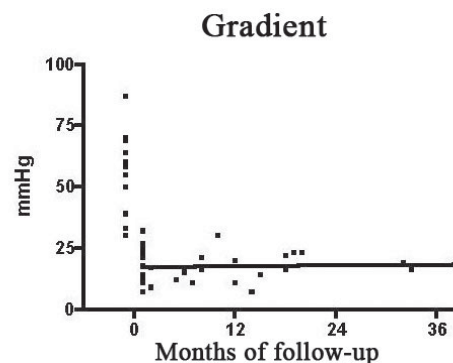


Fig. 4 – Postoperative gradient evolution along the follow-up period.

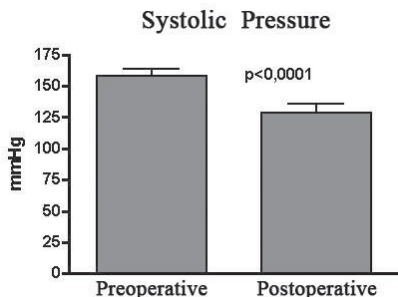


Fig. 5 – Systolic Pressure behavior in the preoperative and postoperative periods. SP = systolic pressure; mmHg = millimeters of mercury.

According to the clinical standpoint, out of 45 patients evaluated, 42 (93.3%) were found asymptomatic and 3 (6.7%) with mild intensity symptoms (myocardial insufficiency I and II).

Regarding the control of arterial pressure, 41 (91.1%) patients were found normotensive (mean pressure of 127 X 76 mmHg) and 4 (8.9%) still remained hypertensive, using medication; 34 (75.6%) patients were not taking any sort of anti-hypertensive medication and 11 (24.4%) were under medication, being 9 (20%) under one medication (beta-blocking agent preferably) and 2 (4.4%) under two medications (beta-blocking agent and diuretic drugs). The behavior of the systolic arterial pressure during the postoperative evolution is shown in Figure 6.

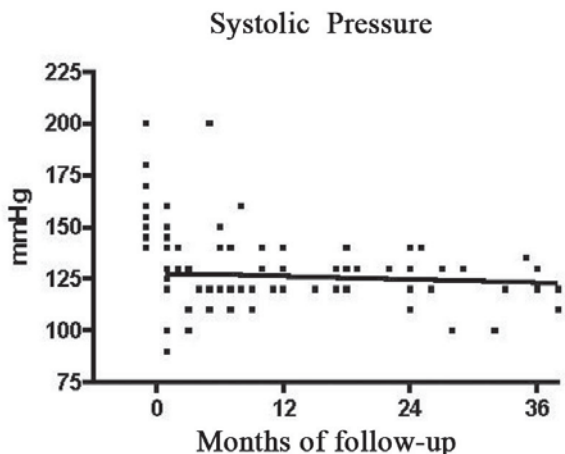


Fig. 6 – Systolic Pressure along the follow-up period. SP = systolic pressure; mmHg = millimeters of mercury.

DISCUSSION

Considering the surgical techniques used for the aortic coarctation correction, some aspects should be observed, in order to obtain good results and prevent eventual recurrence of the aortic coarctation ; amongst these it can be cited that the resection of the coarctate area jointly with the ductal tissue have an important role in preventing problems. In neonates and infants, the resection of the aortic coarctation technique and end-to-end anastomosis is being precognized as the technique of preference, due to the possibility of growth of the aorta and low rate of recoarctation [16]. Sanches et al. [17] suggested that abnormalities of the periductal tissue in the aorta wall might be responsible for the restenosis in 22% of the operated patients, in the period from 6 weeks to 66 months and, in adults, it is not always possible to perform the resection of the coarctate area, due to the local anatomical conditions, such as the presence of caliber collaterals, difficulty of mobilization of the aorta, as well as hypoplastic segments of the aorta next to the aortic coarctation. Therefore, other techniques can be used, minimizing risks of bleeding caused by excessive manipulation and local dissection, such as enlargement of the coarctate area with patches (bovine pericardium or Gore-tex), interposition or bypass of synthetic tubes. Heinemann et al. [8] indicate the extra-anatomical bypass in the following conditions: complex coarctation, reoperations, extensive aortic occlusive disease and complicated aneurisms, although this last condition is considered to be an exception.

In our experience, in only 40% of the cases, the resection of the coarctate area with end-to-end anastomosis was possible; in 60% of the cases of our series, the resection was not possible, having been performed the enlargement of the coarctate area with bovine pericardial graft (44%) and synthetic tube interposition (16%). Bouchart et al. [7] refer the end-to-end anastomosis for correction of 86% of the aortic coarctation cases with mean age of 28 years, reminding the importance of extensive mobilization of the entire aorta (arch, base vessels and descending aorta). Aris et al. [18], in experience with patients with aortic coarctation aged over 50 years, report the usage of Dacron tubes, performing bypass of the aortic coarctation. Oliveira et al. [19], in 29 patients; performed: aortoplasty without graft in 9 (31%), aortoplasty with graft in 18 (62%), end-to-end anastomosis in 1 (3.5%) and aortoplasty with subclavian artery in 1 (3.5%).

In the adult patient, expectations on the necessary growth of the aorta are minimized, thus allowing more options in the usage of referred techniques, with less probability of recurrence of the aortic coarctation. The aortic coarctation aortoplasty employing the Dacron patch was considered effective and safe by Venturini et al. [20], with

the occurrence of aneurismal formation in only one of the 60 patients. On the other hand, Parks et al. [21], in 39 patients being followed-up, 10 presented aortic rupture, discontinuing this technique. Silva [22] emphasized the good results achieved in 3 patients followed-up for 30 years using pediculate pericardium, with no aneurismal formation. In our series, the cases in which enlargement of the coarctate area with patch was used, there were found no evidences of aneurismal formation.

Another important aspect refers to the risk of bleeding during the opening of the thorax and dissection of the structures adjacent to the aortic coarctation, due to the presence of large collaterals close to the aorta, as well as the superficial and intercostal muscular planes [13,14]. Additional care must be taken during the opening, performing accurate control of the blood pressure, due to the presence of HBP in the large majority of patients.

Sweeney et al. [23] report the occurrence of bleeding and hemodynamics instability. In our series of cases, there were no problems related to bleeding during the thorax opening and only one patient required reoperation for bleeding, with positive evolution.

Regarding the postoperative events, in addition to the risk of postoperative bleeding, observed in one of our patients, HBP represented the most frequent occurrence. In our experience, as expected, the majority of the patients presented HBP in the immediate postoperative period, requiring the use of endovenous medication for control.

SH was present in 81.8% of the patients in the experience of Oliveira et al. [19].

In addition to HBP, complications such as neurological or motor disturbances were observed [24]; in our experience no patient presented neurological complications. Lisboa et al. [11] also reported the absence of neurological complications with extra-anatomical techniques. In our series, there were no complications such as ventricular dysfunction or arrhythmias in the postoperative period, being observed the presence of left ventricular hypertrophy, as found previously described in all patients in the preoperative period by the echocardiogram. Also, in our series, there were no pulmonary infection complications or of any sort.

As for the HBP control, the idea of removing the mechanical obstacle that caused increase in blood pressure may suggest that there is pressure stabilization in all patients; however, such fact is not a constant. As observed by Hager et al. [24], in a study involving 404 patients followed-up in a period from 1 to 27 years, the majority of the patients remained hypertensive in the long-term, whereas only a minority of the cases presented gradients higher than 20 mmHg and 43% of the patients undergone surgical correction of the aortic coarctation presented blood pressure stabilization. Unlike some reports, in our study,

more than 90% of patients presented blood pressure stabilization in the postoperative evolution period, with or without the use of medication. We believe that the efficient relief of stenosis, regardless of the technique used, might be an important factor in the control of HBP. However, in approximately 25% of the patients, it is required the use of one or more anti-hypertensive drugs, for the control of the SH. Bouchart et al. [7] observed that, in 35 operated patients; 23 became normotensive without medication, 6 with monotherapy and 6 with anti-hypertensive medication.

The fact that not all the patients presented blood pressure stabilization can be explained by the longer time of preoperative HBP, noting less elasticity in the aortic wall, at times even presenting fibrosis and calcification in the region next to the coarctate area, which, besides making surgical correction difficult, prevents adequate control of the arterial pressure. The persistence of HBP in the postoperative period may be associated to multiple factors, such as the persistence of endocrine factors and/or the reduction of the vascular bed complacence next to the aortic coarctation [25], factors not changed with the surgery. Such aspects could not be evaluated in the patients of our series, which makes it difficult to construe the high incidence of control of the HBP in the patients operated by our group; although, besides the relief of stenosis, another factor that could, in our opinion, be related to the HBP control, would be, in our patients, the mean age under 25 years that could be related to less fibrosis and better vascular complacence. Other authors correlated the persistence of hypertension in the postoperative to the existence of a residual gradient higher than 30 mmHg [25]. In our series, the postoperative gradient observed by the echocardiogram was lower than 20 mmHg, which would be an extra factor that could possibly explain the high incidence of HBP control. Another factor related may be a lower capacity of regulating the blood pressure, due to the lower sensitivity of the blood pressure sensors, located in different spots, along the aorta.

As for the most frequent medication applied in the postoperative control of the blood pressure, it can be observed the large variability amongst different groups, with the application of different drugs, as well as associations of one or more medicines.

In our study, the cases in which preoperative medication was required, the beta-blocking agents were the drug of choice, exclusively or in association with different types of diuretic drugs.

In the last few years, the endovascular treatment by balloon or endoprosthesis has been performed more frequently, despite the higher incidence of restenosis in these patients [26]. Tyagy et al. [27] recommend the use of nitinol endoprosthesis for the correction of unsatisfactory results with the angioplasty by balloon. Karl [28] considers that the best treatment for aortic coarctation is the surgical

one for most of the cases, considering the results in the long-term.

Based on the data acquired with this study, we can conclude that the surgical treatment of aortic coarctation can be performed with efficient results regardless of the technique applied, with low morbidity and mortality, reducing the pressure levels in the mid-term follow-up, with or without the use of anti-hypertensive medication, even in adult patients.

REFERENCES

1. Vosschulte K. Surgical correction of coarctation of the aorta by an "isthmoplasty" operation. *Thorax*. 1961;16:338-45.
2. Campbell M. Natural history of coarctation of the aorta. *Br Heart J*. 1970;32(5):633-40.
3. Grech V. Diagnostic and surgical trends, and epidemiology of coarctation of the aorta in a population-based study. *Int J Cardiol*. 1999;68(2):197-202.
4. Koller M, Rothlin M, Senning A. Coarctation of the aorta: review of the 362 operated patients. Long-term follow-up and assessment of prognostic variables. *Eur Heart J*. 1987;8(7):670-9.
5. Cohen M, Fuster V, Steele PM, Driscoll D, McGoon DC. Coarctation of the aorta. Long-term follow-up and prediction of outcome after surgical correction. *Circulation*. 1989;80(4):840-5.
6. Trojnarzka O, Gwizdala A, Lanocha M, Katarzynska A, Katarzynski S, Oko-Sarnowska Z, et al. Exercise testing in adults after repair of aortic coarctation: evaluation of cardiopulmonary exercise capacity and B-type natriuretic protein levels. *Tex Heart Inst J*. 2007;34(4):412-9.
7. Bouchart F, Dubar A, Tabley A, Litzler PY, Haas-Hubscher C, Redonnet M, et al. Coarctation of the aorta in adults: surgical results and long-term follow-up. *Ann Thorac Surg*. 2000;70(5):1483-8.
8. Heinemann MK, Ziemer G, Wahlers T, Köhler A, Borst HG. Extraanatomic thoracic aortic bypass grafts: indications, techniques, and results. *Eur J Cardiothorac Surg*. 1997;11(1):169-75.
9. Oliveira SA, Lisboa LA, Dallan LA, Abreu Filho CA, Rochitte CE, Souza JM. Extraanatomic aortic bypass for repair of aortic arch coarctation via sternotomy: midterm clinical and magnetic resonance imaging results. *Ann Thorac Surg*. 2003;76(6):1962-6.
10. Berdat PA, Göber V, Carrel T. Extra-anatomic aortic bypass for complex (re-) coarctation and hypoplastic aortic arch in adolescents and adults. *Interact Cardiovasc Thorac Surg*. 2003;2(2):133-7.
11. Lisboa LAF, Abreu Filho CA, Dallan LAO, Rochitte CE, Souza JM, Oliveira SA. Tratamento cirúrgico da coarctação do arco aórtico em adulto: avaliação clínica e angiográfica tardia da técnica extra-anatômica. *Rev Bras Cir Cardiovasc*. 2001;16(3):187-94.
12. Carvalho MVH, Pereira WL, Gandra SMA, Rivetti LA. Coarctação de aorta no adulto: a respeito de um caso e sobre desvios extra-anatômicos. *Rev Bras Cir Cardiovasc*. 2007;22(4):501-4.
13. Croti UA, Braile DM, Finoti RG, Bonatto RC. Coarctação de aorta: interposição de enxerto tubular na presença de aneurisma pós-endocardite. *Rev Bras Cir Cardiovasc*. 2007;22(2):257-8.
14. Owens WA, Tolan MJ, Cleland J. Late results of patch repair of coarctation of the aorta in adults using autogenous arterial wall. *Ann Thorac Surg*. 1997;64(4):1072-4.
15. Blackstone EH. Breaking down barriers: helpful breakthrough statistical methods you need to understand better. *J Thorac Cardiovasc Surg*. 2001;122(3):430-9.
16. Deleon SY, Desikacharlu A, Dorotan JG, Lane J, Cvetkovic DR, Myers JL. Modified extended end-to-end repair of coarctation in neonates and infants. *Pediatr Cardiol*. 2007;28(5):355-7.
17. Sánchez GR, Balsara RK, Dunn JM, Mehta AV, O'Riordan AC. Recurrent obstruction after subclavian flap repair of coarctation of the aorta in infants. Can it be predicted or prevented? *J Thorac Cardiovasc Surg*. 1986;91(5):738-46.
18. Aris A, Subirana MT, Ferrés P, Torner-Soler M. Repair of aortic coarctation in patients more than 50 years of age. *Ann Thorac Surg*. 1999;67(5):1376-9.
19. Oliveira SA, Carneiro BBS, Lima RC, Cavalcanti C, Villachan R, Arraes N, et al. Tratamento cirúrgico da coarctação da aorta: experiência de três décadas. *Rev Bras Cir Cardiovasc*. 2007;22(3):317-21.

-
20. Venturini A, Papalia U, Chiarotti F, Caretta Q. Primary repair of coarctation of the thoracic aorta by patch graft aortoplasty. A three-decade experience and follow-up in 60 patients. *Eur J Cardiothorac Surg.* 1996;10(10):890-6.
 21. Parks WJ, Ngo TD, Plauth WH Jr, Bank ER, Sheppard SK, Pettigrew RI, et al. Incidence of aneurysm formation after Dacron patch aortoplasty repair for coarctation of the aorta: long-term results and assessment utilizing magnetic resonance angiography with three-dimensional surface rendering. *J Am Coll Cardiol.* 1995;26(1):266-71.
 22. Silva PR. Retalho de pericárdio pediculado vascularizado autógeno para aortoplastia e correção da coarctação simples de aorta torácica, ou associada à hipoplasia, atresia ou interrupção do arco aórtico. *Rev Bras Cir Cardiovasc.* 2006;21(4):453-60.
 23. Sweeney MS, Walker WE, Duncan JM, Hallman GL, Livesay JJ, Cooley DA. Reoperation for aortic coarctation: techniques, results, and indications for various approaches. *Ann Thorac Surg.* 1985;40(1):46-9.
 24. Hager A, Kanz S, Kaemmerer H, Schreiber C, Hess J. Coarctation long-term assessment (COALA): significance of arterial hypertension in a cohort of 404 patients up to 27 years after surgical repair of isolated coarctation of the aorta, even in the absence of restenosis and prosthetic material. *J Thorac Cardiovasc Surg.* 2007;134(3):738-45.
 25. Clarkson PM, Nicholson MR, Barratt-Boyes BG, Neutze JM, Whitlock RM. Results after repair of coarctation of the aorta beyond infancy: a 10 to 28 year follow-up with particular reference to late systemic hypertension. *Am J Cardiol.* 1983;51(9):1481-8.
 26. Carr JA. The results of catheter-based therapy compared with surgical repair of adult aortic coarctation. *J Am Coll Cardiol.* 2006;47(6):1101-7.
 27. Tyagi S, Singh S, Mukhopadhyay S, Kaul UA. Self- and balloon-expandable stent implantation for severe native coarctation of aorta in adults. *Am Heart J.* 2003;146(5):920-8.
 28. Karl TR. Surgery is the best treatment for primary coarctation in the majority of cases. *J Cardiovasc Med (Hagerstown).* 2007;8(1):50-6.