

Multidisciplinary Approach to Right Ventricular Myxoma

Ali Karagöz¹, MD; Berhan Keskin¹, MD; Ahmet Karaduman¹, MD; Seda Tanyeri¹, MD; Taylan Adademir², MD



DOI: 10.21470/1678-9741-2020-0177

Abstract

Right ventricular (RV) myxoma that obstructs the RV outflow tract is rare. Multimodality imaging is crucial due to the curved and triangular shape of the RV anatomy. Incomplete resection by the right atrial approach in cardiac myxomas may be prevented by preoperative imaging with echocardiography, computed tomography and magnetic resonance imaging to provide detailed visualization. Right ventriculotomy may be an alternative approach to the isolated atrial approach to get complete resection of RV myxoma in suitable patients. The preferred surgical treatment is

not well defined for ventricular myxomas and careful preoperative planning is essential. Surgical resection should be performed as soon as possible to avoid outflow tract obstruction, which might result in sudden death. The collaboration between cardiologist and heart surgeon and the effective use of imaging tools are essential for successful treatment. In this article, diagnosis and treatment and the heart team approach to RV myxoma are discussed with a demonstrative patient.

Keywords: Cardiac Tumors (Incl Primary, Metastatic). Myxoma, Imaging (All Modalities; Specify Target).

Abbreviations, acronyms & symbols

CMR	= Cardiac magnetic resonance
CT	= Computed tomography
RV	= Right ventricle
2D-TTE	= Two-dimensional transthoracic echocardiography

INTRODUCTION

Cardiac myxomas are benign tumors of endocardial origin. Symptoms might mimic heart disease as well as infectious disease, immunodeficiency, and malignant processes. Myxomas arise from right ventricle (RV) in 3.7% of cases; however, myxomas originating in the RV free wall are rare and not a well-defined pathologic process in the literature^[1].

Due to the complex shape of the RV, it is difficult to generate images of its components simultaneously by using two-dimensional transthoracic echocardiography (2D-TTE). Cardiac

magnetic resonance (CMR) plays an important role in the evaluation of cardiac masses, especially when echocardiographic findings are suboptimal, or when the localization is atypical. The evaluation of regional wall motion abnormalities and tissue characterization are only possible with CMR. Multimodality imaging is an important concept for the diagnosis and treatment process. In this article, we present a patient with recurrent RV myxoma evaluated by multimodality imaging and successfully managed.

TECHNIQUE

A 26-year-old man was referred to our clinic with recurrent cardiac tumor, which was operated by atrial approach two months ago. We detected a large RV myxoma connected to the basal free wall and anterior leaflet of the tricuspid valve with 2-D TTE, CMR and computed tomography (CT) (Figure 1A and 1B, Video 1 to 3). CMR revealed a huge (6.57×3.33 centimeters) mobile heterogeneous mass (Figure 1C). The 2-D TTE showed that a myxoma caused partial RV inflow obstruction (Video 4).

¹Department of Cardiology, Kartal Kosuyolu Research and Education Hospital, Kartal, İstanbul, Turkey.

²Department of Cardiovascular Surgery, Kartal Kosuyolu Research and Education Hospital, Kartal, İstanbul, Turkey.

This study was carried out at the Department of Cardiology and Cardiovascular surgery, Kartal Kosuyolu Research and Education Hospital, Kartal, İstanbul, Turkey.

Correspondence Address:

Ali Karagöz

<https://orcid.org/0000-0002-0438-2021>

Kartal Koşuyolu Yüksek İhtisas Eğitim ve Araştırma hastanesi

Denizer caddesi Cevizli Kavşağı No: 2, Kartal, İstanbul, Turkey

Zip code: 34730

E-mail: draliko@yahoo.com

Article received on April 19th, 2020.

Article accepted on May 21st, 2020.

Cardiac CT showed that the basal free wall of RV was invaded by the myxoma and the RV was mildly dilated (Figure 1B). Gadolinium-enhanced CMR imaging revealed heterogeneous delayed enhancement in RV mass, confirming the diagnosis of myxoma (Figure 1D).

The heart was exposed after re-sternotomy and release of adhesions. Aortic arterial and selective bicaval cannulation were done after systemic heparinization. Right atriotomy was performed under total cardiopulmonary bypass and exposed only part of the mass through the tricuspid valve. Thus, the

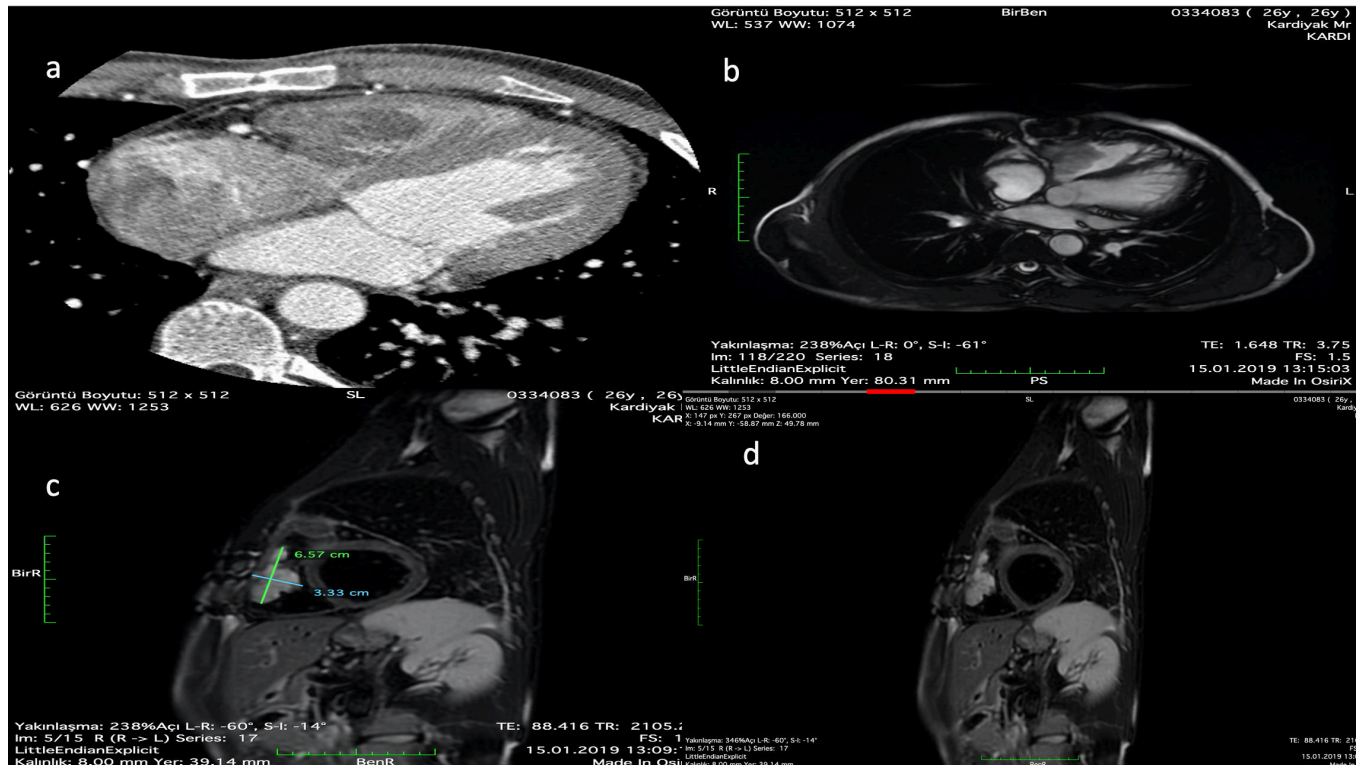


Fig. 1 – (A) Computed tomography shows right ventricular myxoma that is connected to right ventricular basal free wall. (B) Four-chamber MRI view shows right ventricular myxoma that is connected to the right ventricular basal free wall. (C) MRI short-axis view shows the measure of the myxoma in 6,57×3,33 centimeters. (D) Gadolinium-enhanced MRI imaging revealed heterogeneous delayed enhancement of the RV mass confirming the diagnosis of myxoma.

tumor was exposed through a 4-cm long right ventriculotomy incision, perpendicular to the RV outflow tract, starting just below the pulmonary valve. The myxomatous mass that invaded the RV around the tricuspid valve, including the septal valve of the tricuspid valve and muscle of Lancisi, was exposed. The tumor in the RV muscle was excised with a 2-3 mm muscle tissue by using a scalpel. The tumor mass in the tricuspid valve and papillary muscle was scraped and cryoablation (AtriCure™ cryoICE Cryoablation Probe at -60 °C for 2 minutes) was used to naturalize the tumor cells in the valve and papillary muscles. In addition, cryoablation of the tumor base was performed, in our case, where the tumor was suspected, showing deep intramyocardial invasion. Right ventriculotomy was closed primarily with Teflon pledgets and Prolene sutures. Right atriotomy was closed primarily after stabilization of the tricuspid annulus with a De Vega annuloplasty suture. After surgery, imaging showed mild tricuspid regurgitation, with no residual tumor mass (Video 5 to 7). The histologic material obtained after operation was consistent with cardiac myxoma (Figure 2).

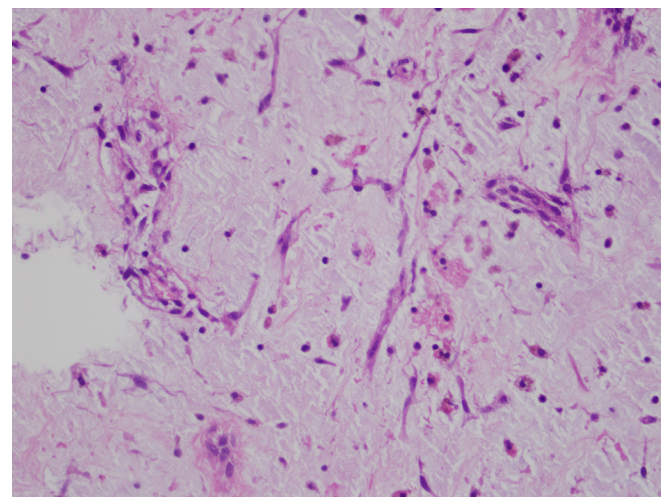


Fig. 2 – Postoperative histological specimen revealed myxoma cells, short strands embedded in the myxoid stroma.



Video 1 - Two-dimensional transthoracic echocardiography, parasternal short axis view, shows right ventricular mass connected to the right ventricular basal free wall.



Video 5 - Postoperative two-dimensional transthoracic echocardiography short axis view shows the absence of a right ventricular mass.



Video 2 - Four-chamber MRI view shows right ventricular mass connected to the right ventricular basal free wall.



Video 6 - Postoperative two-dimensional transthoracic echocardiography four-chamber view shows the absence of a right ventricular mass



Video 3 - Two-dimensional transthoracic echocardiography shows right ventricular mass attached to the anterior leaflet of the tricuspid valve.



Video 7 - Postoperative color Doppler two-dimensional transthoracic echocardiography four-chamber view shows mild tricuspid regurgitation and absence of right ventricular outflow tract obstruction.



Video 4 - Two-dimensional transthoracic echocardiography color Doppler shows the systolic motion of the right ventricular mass and systolic turbulence, which means right ventricular outflow tract obstruction.

DISCUSSION

Despite the low recurrence of myxoma with surgery, a large study showed that, in the univariate Cox regression model analysis, the right ventricular myxoma has a high recurrence with the only right atrial approach^[2]. Although there is no clear explanation for a surgical approach in RV myxomas, right atrial surgical approach and the absence of detailed examination of the tumor's invasion site with multimodality imaging and the curved shape of the right ventricle may cause incomplete resection in our case^[3-5].

This case also highlights the need for noninvasive imaging modalities in the delineation of cardiac masses before contemplating surgical planning and the importance of heart team approach. Tumor seeding, incomplete removal, multiple tumor foci and malignancy can be causes of recurrence; however, insufficient preoperative imaging that causes inadequate surgery can be an important reason for treatment failure^[4,5].

Authors' roles & responsibilities

AK	Substantial contributions to the conception or design of the work; or the acquisition, analysis, or interpretation of data for the work; drafting the work or revising it critically for important intellectual content; final approval of the version to be published
BK	Substantial contributions to the conception or design of the work; or the acquisition, analysis, or interpretation of data for the work; drafting the work or revising it critically for important intellectual content; final approval of the version to be published
AK	Agreement to be accountable for all aspects of the work in ensuring that questions related to the accuracy or integrity of any part of the work are appropriately investigated and resolved; final approval of the version to be published; final approval of the version to be published
ST	Agreement to be accountable for all aspects of the work in ensuring that questions related to the accuracy or integrity of any part of the work are appropriately investigated and resolved; final approval of the version to be published; final approval of the version to be published
TA	Agreement to be accountable for all aspects of the work in ensuring that questions related to the accuracy or integrity of any part of the work are appropriately investigated and resolved; final approval of the version to be published; final approval of the version to be published

CONCLUSION

We used multimodality imaging and made preoperative planning with the heart team to provide surgical success. We decided on the right atrial and ventricular approach to provide complete resection. This experience underlines the importance of teamwork and detailed preoperative preparation. The use of both ventricular and atrial approach may be useful in the treatment of challenging RV myxomas.

No financial support.

No conflict of interest.

REFERENCES

1. McAllister HA Jr, Fenoglio JJ Jr. Tumors of the cardiovascular system. Atlas of tumor pathology. 2nd series. Fascicle 15. Washington, D.C.: Armed Forces Institute of Pathology, 1978:1-20.
2. Shah IK, Dearani JA, Daly RC, Suri RM, Park SJ, Joyce LD, et al. Cardiac myxomas: a 50-year experience with resection and analysis of risk factors for recurrence. *Ann Thorac Surg.* 2015;100(2):495-500. doi:10.1016/j.athoracsur.2015.03.007.
3. Khaliq OK, Cavalcante JL, Shah D, Guta AC, Zhan Y, Piazza N, et al. Multimodality imaging of the tricuspid valve and right heart anatomy. *JACC Cardiovasc Imaging.* 2019;12(3):516-31. Erratum in: *JACC Cardiovasc Imaging.* 2019;12(12):2611-2. doi:10.1016/j.jcmg.2019.01.006.
4. Reynen K. Cardiac myxomas. *N Engl J Med.* 1995;333(24):1610-7. doi:10.1056/NEJM199512143332407.
5. Gray IR, Williams WG. Recurring cardiac myxoma. *Br Heart J.* 1985;53(6):645-9. doi:10.1136/hrt.53.6.645.



This is an open-access article distributed under the terms of the Creative Commons Attribution License.