

Results of beating heart mitral valve surgery via the trans-septal approach

Resultados da abordagem transeptal para a valva mitral com coração batendo

Tomas A. SALERNO¹, Maria SUAREZ², Anthony L. PANOS³, Francisco Igor MACEDO⁴, Julia ALBA⁵, Michael BROWN⁶, Marco RICCI⁷

RBCCV 44205-1044

Abstract

Objective: Mitral valve surgery can be performed through the trans-atrial or the trans-septal approach. Although the trans-atrial is the preferred method, the trans-septal approach has also been used recently and has a particular value in beating-heart mitral valve surgery. Herein we report our experience with beating-heart mitral valve surgery via trans-septal approach, and discuss its advantages and pitfalls.

Methods: Between 2000 and 2007, 214 consecutive patients were operated upon utilizing beating heart technique for mitral valve surgery. The operation was performed via trans-septal approach with the aorta unclamped, the heart beating, with normal electrocardiogram and in sinus rhythm.

Results: Mean age was 56.03 ± 13.93 years (range: 19-86 years; median: 56 years). There were 131 (61.2%) males and 83 (38.8%) females. Of the prostheses used, 108 (50.5%) were biological, and 39 (18.2%) were mechanical. Mitral repairs were performed in 67 (31.3%) patients. Mean hospital stay was 17.4 ± 20.0 days (range: 3-135 days; median: 11 days). Intra-aortic balloon pump (IABP) utilization was required in 12 (5.6%) of 214 patients. One-month mortality was 7.4%, and re-operation for bleeding was needed in 15 (7%) patients.

Conclusions: Beating-heart mitral valve surgery is an option for myocardial protection in patients undergoing mitral valve surgery. This technique is facilitated by the trans-septal approach due to reduced aortic insufficiency and improved visualization of the mitral apparatus.

Descriptors: Mitral valve, surgery. Heart valves, surgery. Heart valve diseases. Heart arrest, induced.

Resumo

Objetivo: A cirurgia da valva mitral pode ser feita via transatrial ou transeptal. Embora a transatrial seja a preferida, a via transeptal tem sido utilizada mais recentemente e tido um grande valor nas operações com o coração batendo. Mostramos a nossa experiência na cirurgia da valva mitral via transeptal com coração batendo e discutimos seus benefícios e problemas.

Métodos: Entre 2000 e 2007, 214 pacientes consecutivos foram operados com o coração batendo. A operação foi feita por via transeptal sem pinçamento da aorta, com o coração batendo e eletrocardiograma normal e em ritmo sinusal.

Resultados: A idade média foi de $56,03 \pm 13,93$ anos (intervalo: 19-86 anos; mediana: 56 anos). Havia 131 (61,2%) pacientes do sexo masculino e 83 (38,8%), do feminino. Foram

1. Head Professor
2. PhD (researcher)
3. Associated Professor (physician)
4. Medicine Student
5. PhD
6. Perfusionist
7. Associated Professor (surgeon)

Correspondence address:

Tomas A. Salerno
1611 nw 12th avenue, Miami, Florida USA 33136.
E-mail: tsalerno@med.miami.edu

This study was carried out at the University of Miami Miller School of Medicine and Jackson Memorial hospital, Miami, Florida

Article received on January 13rd, 2009
Article accepted on February 20th, 2009

utilizadas 108 (50,5%) próteses biológicas e 39 (18,2%) mecânicas. Reparo da valva foi feito em 67 (31,3%) pacientes. A estadia hospitalar foi de $17,4 \pm 20,0$ dias (intervalo: 3-135 dias; mediana: 11 dias). Balão intra-aórtico foi utilizado em 12 (5,6%) pacientes. A mortalidade hospitalar foi de 7,4%. Reoperação para revisão de hemostasia foi necessária em 15 pacientes.

Conclusão: A operação com o coração batendo é uma opção para proteção miocárdica em pacientes submetidos a cirurgia

da valva mitral. A técnica é facilitada ao se usar a via transeptal, reduzindo a insuficiência aórtica e melhorando a visualização do aparato mitral.

Descritores: Valva mitral, cirurgia. Valvas cardíacas, cirurgia. Doenças das valvas cardíacas. Parada cardíaca induzida.

INTRODUCTION

Although beating heart surgery had been used in the early days of cardiac surgery, it was only recently that several surgical groups including ours [1,2] reported mitral valve surgery without cardioplegia. The operation is performed on a beating heart, minimizing or eliminating ischemia-reperfusion injury due to aortic cross-clamping and myocardial ischemia. Several surgical approaches to the mitral valve have been proposed in the literature. When cold blood cardioplegic arrest and cross-clamping of the aorta are used, mitral valve surgery is most commonly performed via the trans-atrial approach.

The type of surgical approach to the mitral valve is particularly important in beating-heart mitral valve surgery. Although initially performed via conventional trans-atrial approach, our beating-heart approach to the mitral valve has evolved into the trans-septal approach [3] because retraction of the atrial wall during the trans-atrial approach often caused aortic insufficiency. Several types of trans-septal approach have been reported previously [4]. These include the technique in which a transverse incision is made that extends medially from the right superior pulmonary vein to the right atrium, and through the inter-atrial septum, as described previously by Dubost et al. [5], the conventional posterior inter-atrial groove incision perpendicular to the septum and the right atrium [6], and the superior trans-septal approach through the right atrium, the left atrium, and the inter-atrial septostum extended to the inferior portion of the fossa ovalis [7].

To our knowledge, there have been no reports focusing on the type of surgical approach to mitral valve surgery using beating-heart technique. As we believe this is an important aspect of this type of surgery, we reviewed our experience with beating-heart, trans-septal, mitral valve operations, discussing its advantages and pitfalls.

METHODS

With Institutional Review Board (IRB) approval for this study, we retrospectively reviewed the medical records of

214 consecutive patients with a variety of mitral valve pathologies who underwent mitral valve surgery utilizing beating heart technique at our institution. This includes all mitral valve patients undergoing mitral valve surgery at our Institution for that period. Demographics are summarized in Table 1. Mitral valve disease was due to myxomatous disease in 66 (30.8%) patients, acute bacterial endocarditis in 40 (18.7%), ischemic mitral insufficiency in 37 (17.3%), rheumatic fever in 33 (15.4%), dilated cardiomyopathy in 19 (8.9%), and prosthetic endocarditis in 19 (8.9%). The mean ejection fraction (EF) was $35.2\% \pm 18.4$ (range: 5-75%; median: 30%). In 15 (14.8%) patients, the EF was below 15%, in 40 (57.4%) patients between 16% and 30%, in 25 (24.8%) patients between 31% and 50%, and in 21 (20.8%) patients greater than 50%.

Table 1. Patients' Clinical Characteristics (n=214)

Variables	N	%
Age		
At surgery	56.0 \pm 13 years	
Range	19-86 years	
Median	56.0 years	
Gender		
Male	131	61.2
Female	83	38.8
Type of Procedure		
Elective	61	28.5
Urgent	116	54.2
Emergent	37	17.3
Salvage	26	12.0
Co-morbidities		
Diabetes mellitus	20	9.3
Hypertension	52	24.3
Congestive heart failure	124	57.9
Sepsis	12	5.6
End stage renal disease	15	7.0
Coronary artery disease	41	19.0
Ejection Fraction (EF)		
Mean EF	35.3 \pm 18.4%	
Range	5-75%	
Median	30.0%	

Surgical procedure

Procedures were performed at systemic temperature of 34°-35°C. After heparinization, the ascending aorta and both cavae were cannulated [3]. Cardiopulmonary bypass (CPB) was initiated and the cavae were snared. The right atrium was open longitudinally and the heart was then briefly fibrillated. A longitudinal incision was made into the fossa ovale, with extension superiorly toward the superior vena cava, and inferiorly to the area just behind the coronary sinus, so as to gain access to the left atrium and expose the mitral valve (Figure 1). A suction catheter was passed through the mitral valve into the left ventricle (Figure 2). The heart was then defibrillated. The remainder of the valve procedure (repair or replacement) was performed with the heart beating [8,9]. In no patients it became necessary to cross-clamp the aorta. In the cases that required valve replacement, every effort was made at preserving the posterior subvalvular apparatus, unless it was involved by calcific process or vegetations. As the inter-atrial septum was closed, the heart was again briefly fibrillated and gently massaged, the ascending aorta was vented, the lungs were briefly inflated, and the inter-atrial suture line was secured when there was no evidence of retained air in the left ventricle. Only then was the heart defibrillated. As complementary maneuvers, the patient was placed in a Trendelenburg position during this period.

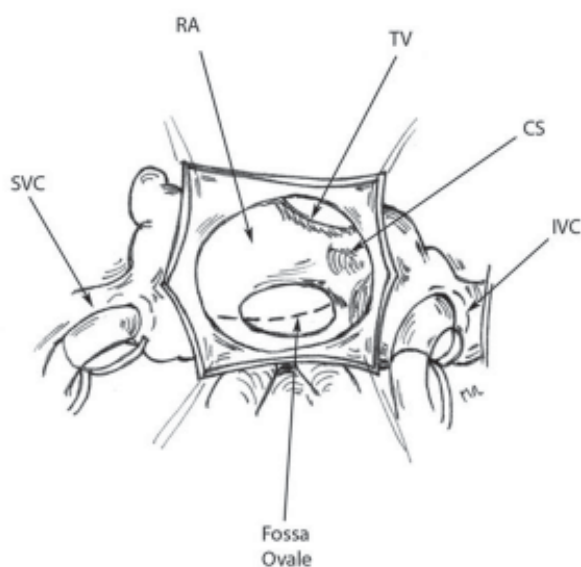


Fig. 1 - General anatomy of the heart during mitral valve surgery. Note the fossa ovale, where the incision into the inter-atrial septum is initially made.

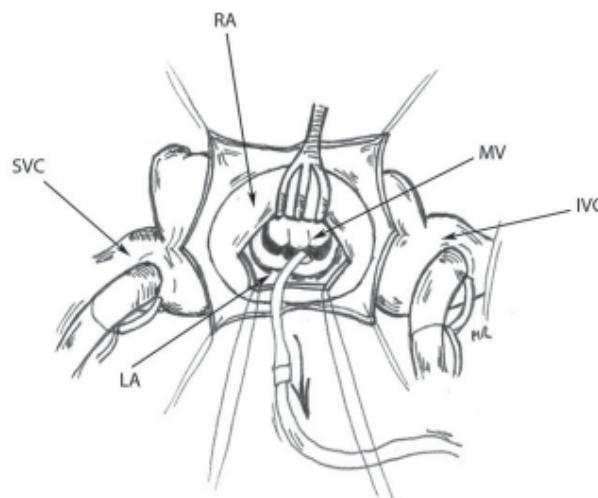


Fig. 2 - Access to the mitral valve after the inter-atrial septum is retracted with a standard mitral retractor. (svc = superior vena cava, RA = right atrium, MV = mitral valve, IVC = inferior vena cava, LA= left atrium, TV= tricuspid valve, CS= coronary sinus).

Occasionally, a suction catheter was inserted in the left ventricle through the apex, as an alternative to inducing ventricular fibrillation when the inter-atrial septum was opened. This also facilitated removal of air from the heart at the end of the procedure. Throughout the procedure the heart was monitored via trans-esophageal echocardiography to ensure that there was no residual air in the atrial or ventricular cavities. There was no evidence of ejection of air into the ascending aorta in any of these patients during surgery.

During combined mitral and aortic valve surgery, both cavae were cannulated and were snared once CPB was initiated. The right atrium was opened and a purse-string was placed around the mouth of the coronary sinus, which was then cannulated. After snaring of the purse-string, perfusion of the coronary sinus was initiated with warm blood at mean pressure of 55 mmHg and flows > 250 ml/min. The aorta was then cross-clamped and opened. Both coronary ostia were cannulated with Polystan cannulae, and the heart was perfused via inflow from the cannula in the ascending aorta. The aortic valve was decalcified and the annulus size was measured. Attention was then directed to the inter-atrial septum which was opened, as described previously. The mitral valve procedure was performed. After the inter-atrial septum had been closed, attention was directed to the aortic valve. The left ventricle was decompressed either via the right superior pulmonary vein, the apex of the heart or through the aortic valve. The aortic valve was replaced and the aorta was closed, utilizing similar

de-airing maneuvers as previously described. If needed, tricuspid repair was performed with the heart beating and the aorta unclamped.

In *combined mitral valve and coronary artery bypass surgery*, coronary bypass was usually performed off-pump, after which the patient was placed on CPB. In case of hemodynamic instability, coronary revascularization was completed on-pump, while the heart was maintained beating and continuously perfused. During the period of the mitral valve surgery, all grafts were left open with the aorta unclamped. In cases in which there was mild aortic insufficiency not requiring intervention, pressure on the root of the aorta from the outside usually eliminated aortic insufficiency.

Statistical analysis

All numerical values were expressed as mean \pm standard deviation. Statistical comparisons for selected numerical variables were made by using the two-tailed chi square Fisher's test. *P* values of less than 0.05 were considered significant.

RESULTS

There were 61 (28.5%) elective, 37 (17.3%) emergent and 116 (54.2%) urgent surgeries. Among them, 26 (12.1%) were classified as "salvage" operations (Table 1). "Salvage" operations were defined as those performed under extreme conditions, i.e., in critically ill patients with at least two of the following conditions; ventilator-dependency, cardiogenic shock, severe metabolic acidosis, septic shock, recent history of cardiac arrest and cardiopulmonary resuscitation, end-stage renal disease, and liver failure.

In regard to the type of surgical procedure (Table 2), the most common operations were mitral valve replacement (143 patients; 66.8%) and mitral valve repair (68 patients; 31.7%). Concomitant valve procedures were performed in 82 (38.3%) patients. These included mitral valve replacement with tricuspid valve repair (17 patients; 7.9%), mitral valve replacement with aortic valve replacement (14 patients; 6.5%), and mitral valve repair with tricuspid valve repair (13 patients; 6%). Coronary artery bypass grafting (CABG) was simultaneously performed in 30 (14%) patients. Other associated-mitral valve surgeries utilizing beating heart technique are listed in Table 2.

There was one case of triple valve surgery performed with concomitant CABG. Mean prosthetic mitral valve size was 28.6 mm \pm 1.7 (range: 25-33 mm) and 29.4 mm \pm 2.3 (range: 25-33 mm) for biological and mechanical valve prostheses, respectively. The cardiopulmonary bypass time for this group of patients was 93.9 \pm 47.9 minutes. Postoperative complications are listed in Table 3. These were identified in 20.5% of 214 patients. The most frequent

was mediastinal bleeding requiring re-exploration in 5 (2.3%) cases, and CHF in 5 (2.3%) cases. Six (2.2%) patients who developed complications died early postoperatively.

Table 2. Concomitant Mitral Valve Operations

Procedure	N	%
Mitral Valve Replacement		
MVRep + TVR	17	20.7
MVRep + CABG	15	18.3
MVRep + AVRep	14	17
MVRep + TVR + CABG	2	2.4
MVRep + AVR + CABG	1	1.2
Mitral Valve Repair		
MVR + TVR	13	15.8
MVR + CABG	10	12.2
MVR + AVRep	3	3.7
MVR + AVR	3	3.7
MVR + AVRep + TVR	2	2.4
MVR + AVR + CABG	1	1.2
MVR + AVRep + TVR + CABG	1	1.2
TOTAL	82	100

MV = mitral valve; *AV* = aortic valve; *TV* = tricuspid valve; *Rep* = replacement; *R* = repair; *CABG* = coronary artery bypass grafting

Table 3. Postoperative Complications

Major complications	N	%
Bleeding	15	7
Congestive heart failure	5	2.3
Cardiac tamponade	5	2.3
Cardiogenic shock	4	1.86
Respiratory insufficiency	4	1.86
Renal failure	3	1.4
Brain emboli	2	0.93
Failed mitral valve repair	2	0.93
Stroke	1	0.46
Myocardial infarction	1	0.46
Sepsis	1	0.46
Mediastinitis	1	0.46

Mechanical support by intra aortic balloon pump (IABP) was required in 12 (5.6%) of 214 patients, while in two (0.93%) cases IABP was utilized preoperatively. Mean hospital stay was 17.4 \pm 20.0 days (range: 3-135 days, median: 11 days). Overall 1-month mortality was 7.4% (16

out of 214 patients). Mortality was significantly lower in patients undergoing urgent/emergent surgical procedures (3.2%; 5/153 patients) as compared to patients undergoing salvage operations (44%; 11/25 patients) (two-tailed $P=0.0001$). Causes of mortality during the first month after the mitral valve surgery were multiple organ failure and postoperative low cardiac output in two and four patients, respectively. One patient died from complications resulting from a stroke occurring 23 days after surgery.

Based on the CT appearance of a localized area of ischemia, it is unlikely that this was due to air embolism. It is more consistent with a particulate matter embolization from the valve. We did not observe any complications resulting from the insertion of catheters in the coronary ostia during aortic valve surgery in patients requiring combined mitral and aortic valve operations. Also, we did not observe any cases of postoperative right ventricular failure or postoperative stroke resulting from intra-operative air embolization.

DISCUSSION

Mitral valve surgery is most commonly performed using the trans-atrial approach under aortic cross-clamping and cardioplegic arrest conditions. Several reports have appeared in the literature regarding surgical procedures utilizing beating-heart techniques in which aortic cross-clamping and cardioplegic arrest were not used [3,10,11]. Advantages of this method of myocardial protection include avoidance of ischemia-reperfusion injury, performance of surgery in a more physiologic state of the heart, decreased use of inotropic medications, and shorter hospital stay [10-12]. Potential concerns related to this technique may include performance of surgery in a relatively blood-filled field, limited surgical precision due to difficult exposure, risk of air embolization, and limited ability to perform complex mitral valve repair procedures on the beating heart. We initially used the trans-atrial approach for this type of surgery and subsequently evolved to using the trans-septal approach. Reasons for the change in surgical strategy include better exposure of the mitral valve especially in small atria and redo operations, avoidance of aortic insufficiency induced by the mitral retractor, and technically easier de-airing of the heart at the end of the procedure [4]. Potential concerns about this type of surgical approach through the atrial septum include the increased incidence of atrial arrhythmias and complete heart block, as well as residual atrial septal defect due to dehiscence of the atrial suture line. However, in our patients we did not observe either complication, although the incidence of atrial fibrillation remained significant in the range of 20-25%.

Trans-septal beating-heart mitral valve surgery may be especially useful in patients with dilated cardiomyopathy

and decreased left ventricular systolic function, as previously confirmed by others [13]. Conventional myocardial protective strategies may result in postoperative left ventricular dysfunction, especially in patients with preoperative myocardial dysfunction and in those requiring prolonged periods of aortic cross-clamping. Experimental studies by our group [14,15] demonstrated decreased accumulation of extracellular fluid, diminished lactate production, and greater preservation of high energy stores when a strategy of myocardial protection with simultaneous antegrade/retrograde continuous normothermic, normokalemic blood perfusion was used as compared to conventional cardioplegic arrest.

The beating-heart technique eliminates the detrimental effects of ischemia-reperfusion injury and allows for sustained normal myocardial energy metabolism during the period of intra-cardiac repair. This approach to mitral valve surgery has also been found to be useful in patients requiring mitral valve reoperations [16], as well as in those with ischemic mitral insufficiency [17,18], since myocardial ischemic injury is minimized.

In our patients postoperative survival using the beating-heart approach was comparable to contemporary series from the literature [19,20]. The statistically significant difference in early mortality, 44% in patients requiring "salvage" operations and 3.2% in urgent or emergent cases, confirms that surgical outcomes in critically ill patients with multiple co-morbid conditions and multi system organ failure remain poor. It also raises the question as to whether some of these patients requiring "salvage" procedures should be treated medically and be excluded altogether from surgical intervention, irrespective of the surgical approach used.

Possible contraindications to beating-heart mitral valve surgery may include the inability to adequately expose the mitral valve, as well as the presence of large and mobile vegetations in patients with infective endocarditis or large left atrial thrombi, due to the risk of embolization. Should this be the case, the surgeon has the option of using conventional myocardial protection with aortic cross-clamping and cardioplegic arrest. Alternatively, the aorta may be cross-clamped and continue myocardial perfusion may be provided by using a perfusion catheter inserted into the aortic root. Another technique that can help in reducing the risk of systemic embolization is the placement of a left ventricular suction catheter directly through the apex of the left ventricle. This strategy can result in effective left ventricular decompression, may facilitate de-airing of the ventricle, and it may eliminate the need to induce ventricular fibrillation for a short period while entering the left atrium. It is not possible to determine with certainty whether minor neuro-cognitive disorders due to microembolization occurred. We have not performed neuro-cognitive evaluation in these patients, but this is an

important aspect that needs to be further investigated.

The presence of aortic insufficiency may also result in significant blood accumulation in the left ventricle as the mitral retractor is applied, and may represent a relative contraindication to beating-heart mitral valve surgery. In general, however, we have observed that aortic valve distortion, and consequent insufficiency, has been reduced by using a trans-septal approach as compared to a trans-atrial approach. When proper visualization of the mitral valve cannot be obtained, the surgeon has the option of cross-clamping the aorta and proceeding with cardioplegic arrest. This situation was not encountered in this series of patient.

In regard to the type of mitral valve procedure (repair versus replacement), in our experience the indications for performing a valve repair procedure are unchanged when using the beating-heart technique as compared to conventional cardioplegic arrest. When performing beating heart mitral valve replacement, preservation of the subvalvular apparatus is important to prevent ventricular dysfunction [21]. The relatively low proportion of mitral valve repairs in this series (31%) as compared to mitral valve replacement was largely based on the fact that a variety of mitral valve disease processes were observed with significant frequency other than myxomatous degeneration and ischemic mitral valve disease, premiere indications for valve repair procedures. We do recognize, however, that in some cases in which complex repair procedures are needed, the beating-heart technique is technically more difficult and involves a significant learning curve.

We acknowledge that our study has several important limitations. In addition to the relatively small number of patients, we were unable to compare beating-heart patients with patients receiving conventional cardioplegic techniques. The clinical variables affecting outcomes in patients with mitral valve disease are numerous. The small sample size would have precluded a meaningful analysis in a patient population where many variables could have affected outcomes (different valve disease processes, age, EF, risk factors, etc.). Our study suggests that the beating-heart approach to mitral valve surgery has comparable survival to contemporary series in which conventional myocardial protective strategies were used. In fact, it confirms that surgical mortality for critically ill patients requiring salvage operations remains significant, probably as a result of powerful preoperative risk factors and comorbidities. However, our experience suggests that the beating-heart mitral valve surgery is facilitated by using the trans-septal approach. Further studies are needed before the clinical benefits of the beating-heart technique can be demonstrated as compared to conventional myocardial protective strategies.

REFERENCES

1. Tehrani H, Masroor S, Lombardi P, Rosenkranz E, Salerno T. Beating heart aortic valve replacement in a pregnant patient. *J Card Surg.* 2004;19(1):57-8.
2. Di Luozzo G, Panos AL, Lombardi P, Salerno TA. Simultaneous antegrade/retrograde normothermic perfusion with blood (beating heart) for aortic root replacement in acute type-a dissection of the aorta. *J Card Surg.* 2005;20(4):350-2.
3. Salerno TA, Panos AL, Tian G, Deslauriers R, Calcaterra D, Ricci M. Surgery for cardiac valves and aortic root without cardioplegic arrest ("beating heart"): experience with a new method of myocardial perfusion. *J Card Surg.* 2007;22(6):459-64.
4. Nienaber JJ, Glower DD. Minitransseptal versus left atrial approach to the mitral valve: a comparison of outcomes. *Ann Thorac Surg.* 2006;82(3):834-9.
5. Dubost C, Guilmet D, Parades B, Pedeferry G. New technic of opening of the left auricle in open-heart surgery: the transseptal bi-auricular approach. *Presse Med.* 1966;74(30):1607-8.
6. Brawley RK. Improved exposure of the mitral valve in patients with a small left atrium. *Ann Thorac Surg.* 1980;29(2):179-81.
7. Guiraudon GM, Ofiesh JG, Kaushik R. Extended vertical transatrial septal approach to the mitral valve. *Ann Thorac Surg.* 1991;52(5):1058-60.
8. Masroor S, Lombardi P, Tehrani H, Yassin SF, Katariya K, Salerno TA. Beating-heart valve surgery in patients with renal failure requiring hemodialysis. *J Heart Valve Dis.* 2004;13(2):302-6.
9. Di Luozzo G, Lombardi P, Maldonado A, Ricci M, Salerno TA. Concomitant beating-heart mitral valve surgery and coronary artery bypass surgery in patients with compromised ventricular function. *Technol Tech Cardiothorac Vasc Surg.* 2006;1(1):1-4.
10. Matsumoto Y, Watanabe G, Endo M, Sasaki H, Kasashima F, Kosugi I. Efficacy and safety of on-pump beating heart surgery for valvular disease. *Ann Thorac Surg.* 2002;74(3):678-83.
11. Thompson MJ, Behranwala A, Campanella C, Walker WS, Cameron EW. Immediate and long-term results of mitral prosthetic replacement using a right thoracotomy beating heart technique. *Eur J Cardiothorac Surg.* 2003;24(1):47-51.
12. Miyairi T, Matsumoto J, Tanaka K, Mizuno A. Intraoperative assessment of functioning mitral valve. *Ann Thorac Surg.* 1996;61(2):743-5.
13. Ghosh S, Jutley RS, Wraight P, Shajar M, Naik SK. Beating-heart mitral valve surgery in patients with poor left ventricular function. *J Heart Valve Dis.* 2004;13(4):622-7.

-
14. Wang J, Liu H, Salerno TA, Xiang B, Li G, Gruwel M. Does normothermic normokalemic simultaneous antegrade/retrograde perfusion improve myocardial oxygenation and energy metabolism for hypertrophied hearts? *Ann Thorac Surg.* 2007;83(5):1751-8.
 15. Wang J, Liu H, Salerno TA, Li G, Gruwel M, Jackson M. Keeping heart empty and beating improves preservation of hypertrophied hearts for valve surgery. *J Thorac Cardiovasc Surg.* 2006;132(6):1314-20.
 16. Cicekcioglu F, Tutun U, Babaroglu S, Mungan U, Parlar AI, Demirtas E. Redo valve surgery with on-pump beating heart technique. *J Cardiovasc Surg (Torino).* 2007;48(4):513-8.
 17. Katircioglu SF, Cicekcioglu F, Tutun U, Parlar AI, Babaroglu S, Mungan U. On-pump beating heart mitral valve surgery without cross-clamping the aorta. *J Card Surg.* 2008;23(4):307-11.
 18. Gersak B. Mitral valve repair or replacement on the beating heart. *Heart Surg Forum.* 2000;3(3):232-7.
 19. Gillinov AM, Blackstone EH, Nowicki ER, Slisatkorn W, Al-Dossari G, Johnston DR, et al. Valve repair versus valve replacement for degenerative mitral valve disease. *J Thorac Cardiovasc Surg.* 2008;135(4):885-93.
 20. Gillinov AM, Faber C, Houghtaling PL, Blackstone EH, Lam BK, Diaz R, et al. Repair versus replacement for degenerative mitral valve disease with coexisting ischemic heart disease. *J Thorac Cardiovasc Surg.* 2003;125(6):1350-62.
 21. Alsaddique AA. Mitral valve replacement with the preservation of the entire valve apparatus. *Rev Bras Cir Cardiovasc.* 2007;22(2):218-23.