

A variant technique for the surgical treatment of left ventricular aneurysms

Variante técnica para o tratamento cirúrgico de aneurismas do ventrículo esquerdo

Paulo Roberto Barbosa Evora¹, MD, PhD; Paulo Victor Alves Tubino¹, MD; Luis Gustavo Gali², MD; Lafaiete Alves Junior¹, MD; Cesar Augusto Ferreira¹, MD, PhD; Solange Bassetto¹, MD, Antônio Carlos Menardi¹, MD, PhD; Alfredo José Rodrigues¹, MD, PhD; Walter Vilella de Andrade Vicente¹, MD, PhD

DOI 10.5935/1678-9741.20140110

RBCCV 44205-1600

Abstract

Objective: To present a surgical variant technique to repair left ventricular aneurysms.

Methods: After anesthesia, cardiopulmonary bypass, and myocardial protection with hyperkalemic tepic blood cardioplegia: 1) The left ventricle is opened through the infarct and an endocardial encircling suture is placed at the transitional zone between the scarred and normal tissue; 2) Next, the scar tissue is circumferentially plicated with deep stitches using the same suture thread, taking care to eliminate the entire septal scar; 3) Then, a second encircling suture is placed, completing the occlusion of the aneurysm, and; 4) Finally, the remaining scar tissue is oversewn with an invaginating suture, to ensure hemostasis. Myocardium revascularization is performed after correction of the left ventricle aneurysm. The same surgeon performed all the operations.

Results: Regarding the post-surgical outcome 4 patients (40%) had surgery 8 eight years ago, 2 patients (20%) were operated on over 6 years ago, and 1 patient (10%) was operated on

more than 5 years ago. Three patients (30%) were in functional class I, class II in 2 patients (20%) and 2 patients (20%) with severe comorbidities remains in class III of the NYHA. There were three deaths (at four days, 15 days and eight months) in septuagenarians with acute myocardial infarction, diabetes and pulmonary emphysema.

Conclusion: The technique is easy to perform, safe and it can be an option for the correction of left ventricle aneurysms.

Descriptors: Left ventricle aneurysm. Left ventricle aneurysmectomy. Ischemic heart disease. Thoracic surgery.

Resumo

Objetivo: Apresentar uma variante técnica para correção de aneurismas do ventrículo.

Métodos: Após anestesia geral, circulação extracorpórea e proteção miocárdica com cardioplegia sanguínea tépida hiperpotassêmica: 1) O ventrículo esquerdo é aberto através da área

¹Department of Surgery and Anatomy, Faculdade de Medicina de Ribeirão Preto da Universidade de São Paulo (FMRP-USP), Ribeirão Preto, SP, Brazil.
²Department of Medical Clinic Faculdade de Medicina de Ribeirão Preto da Universidade de São Paulo (FMRP-USP), Ribeirão Preto, SP, Brazil.

This study was carried out at Faculdade de Medicina de Ribeirão Preto da Universidade de São Paulo (FMRP-USP), Ribeirão Preto, São Paulo, Brazil.

Financial support: CNPq, FAEPA, HCFMRP-USP

No conflict of interest.

Correspondence address:

Paulo Roberto Barbosa Evora
Rua Rui Barbosa, 367, apt. 15 - Centro, Ribeirão Preto, SP, Brazil
Zip code: 14015-120
E-mail: prbevora@fmrp.usp.br

Abbreviations, acronyms & symbols	
CCS	Canadian Cardiovascular Society
LV	Left ventricular
NYHA	New York Heart Association
SVR	Surgical ventricular reconstruction

de infarto e procede-se a uma cerclagem do endocárdio (poli-propileno 2-0) em torno da zona de transição entre a cicatriz e tecido normal; 2) No passo seguinte, o tecido cicatricial é circularmente plicado com pontos grosseiros e profundos, utilizando o mesmo fio de sutura, tomando cuidado para eliminar toda a cicatriz septal; 3) A seguir, uma segunda cerclagem completa a oclusão do aneurisma, e; 4) Finalmente, o tecido cicatricial restante é submetido a uma sutura invaginante para garantir a hemostasia. Terminada a correção do aneurisma, realiza-se a

INTRODUCTION

According Donst in a paper published in Heart Failure Review Surgical, "Reconstruction of physiological shape and size of a postischemically remodeled left ventricle has been advocated to improve ventricular function and improve patient long-term outcome. What initially started as linear aneurysm resection surgery developed over the years into the endoventricular repair techniques that have also been applied in patients with postischemically dilated ventricles and mainly anterior akinesia"^[1].

In 1985, while describing the circular endoventricular suture, in the transition zone between the scarred tissue and the viable myocardium, Jatene ^[2] introduced the concept of "anatomical reconstruction of the left ventricle". Dor et al.^[3] described the use of the endoventricular suture to rebuild a failing ventricle with an endoventricular patch after extended endocardectomy for ventricular tachycardia. The concept of excluding all the diseased tissue from the cavity, especially the septum, is the basis of the good results^[4]. Afterwards, in 2001, Caldeira & McCarthy described a technique for a "no-patch" repair of left anterior descending aneurysms^[5].

The aim of this paper is to present an option of "no-patch" variant technique to treat left ventricular aneurysms, without arguing whether there is a significant difference from others' techniques or that it is measurably better. The proposed variant technique was previously published^[6], emphasizing that Gomes et al.^[7,8] reported a variant technique that eliminates the use of synthetic materials for left ventricle reconstruction.

METHODS

From July 2005 to March 2014, 10 consecutive patients (65.2±8.2 years-old) with ischemic heart disease underwent the aneurysmectomy surgery described herein. Five

revascularização do miocárdio. Todos os pacientes foram operados pelo mesmo cirurgião.

Resultados: Em relação ao tempo de evolução pós-cirúrgica 4 pacientes (40%) superaram o tempo de 8 anos, 2 pacientes (20%) foram operados há mais de 6 anos e 1 paciente (10%) foi operado há mais de 5 anos. Três pacientes estão em classe funcional I (30%), 2 pacientes em classe II (20%) e 2 em classe III (20%) da NYHA. Ocorreram 3 óbitos (30%) em curto prazo (4 dias, 15 dias e 8 meses) em pacientes septuagenários, infarto agudo do miocárdio menos de 30 dias, diabetes e enfisema pulmonar.

Conclusão: A técnica é segura, tecnicamente fácil, e pode ser uma opção para a correção de aneurismas do ventrículo esquerdo.

Descritores: Aneurisma do ventrículo esquerdo. Aneurismectomia do ventrículo esquerdo. Doença isquêmica do coração. Cirurgia torácica.

patients were male (50%), and five were female (50%). The follow-up period was completed in 2014 by means of office visits. Follow-up consisted of obtaining information about the functional class of congestive heart failure (New York Heart Association [NYHA]), angina (Canadian Cardiovascular Society [CCS]), and nonroutine control echocardiograms. All patients were clinically treated and free of angina and presented severe congestive heart failure (Class IV/NYHA). The surgeries were performed under cardiopulmonary bypass, aortic cross-clamping and antegrade hyperkalemic tepid blood cardioplegia.

Technique

After general balanced anesthesia, cardiopulmonary bypass and blood cardioplegia: 1) The left ventricle is opened through the infarcted area, and an endocardial encircling suture is placed at the transitional zone between the scarred and normal tissue (Figure 1A); 2) In the next step, the scar tissue is circumferentially plicated with deep stitches using the same suture thread (Figure 1B); 3) Then, a second encircling suture is placed, completing occlusion of the the aneurysm, taking care to eliminate the entire septal scar (Figure 1C), and; 4) Finally, the remaining scar tissue is oversewn with an invaginating suture, to ensure hemostasis (Figure 1D). Myocardial revascularizations were performed after the left ventricle reconstruction. The same surgeon carried out all operations.

RESULTS

In seven patients (70%), thrombi were found in the cavities of ventricular aneurysms. Besides the left ventricular aneurysmectomy, nine patients (90%) underwent coronary artery

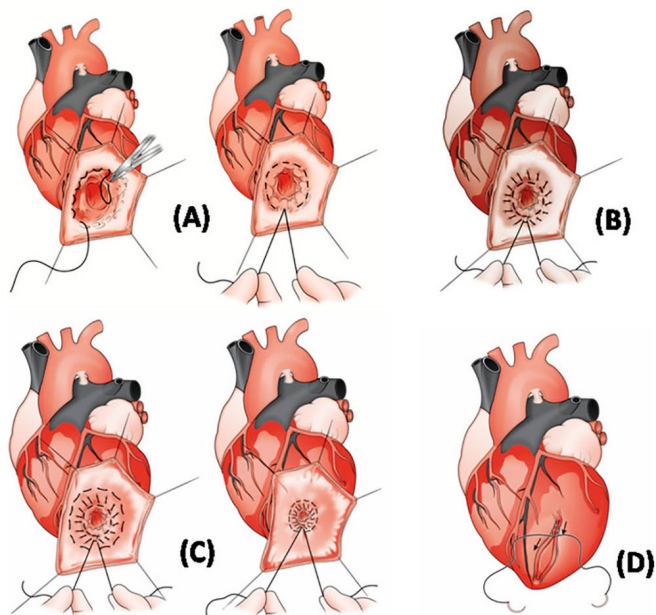


Fig. 1 – A) First endocardial encircling suture around the transitional zone between the scarred and normal tissue; B) Scar tissue plication using the same suture thread (this surgical maneuver keeps the aneurysm neck occluded, preserving the pyriform left ventricle shape); C) Second encircling suture is tightened, completing the aneurysm occlusion; D) The remaining scar tissue is oversewn with a running “out-out” suture, to ensure hemostasis.

bypass grafting, and one patient (10%) underwent coronary artery bypass grafting as well as mitral valve replacement (Table 1). In nine patients, (90%) mechanical circulatory support with intra-aortic balloon pump was used in the first 12 hours postoperatively.

Regarding the post-surgical outcome, four patients (40%) had surgery over eight years ago, two patients (20%) were operated on over six years ago, and one patient (10%) was operated on more than five years ago. Three patients (30%) were in functional class I, class II in 2 patients (20%) and 2 patients (20%) with severe comorbidities remains in class III of the NYHA. There were three deaths (at our days, 15 days and eight months) in septuagenarians with, acute myocardial infarction, diabetes and pulmonary emphysema (Table 1).

Just for illustration purposes, echocardiographic data of five patients operated on more than five years ago is shown (Table 2), in addition to echocardiogram imaging showing the preserved shape of the left ventricle (Figure 2). These data correspond to two years after the reconstruction.

DISCUSSION

Dor was the first surgeon to demonstrate that the endo-ventricular patch plasty repair could be applied not only to left ventricular (LV) aneurysm, but also to a dilated akinetic ischemic LV. He emphasized the concept of reducing the LV size and reconstructing a more elliptical cavity, treating the dilatation in all its components (anterior, apical and septal). The concept of excluding all the diseased tissue from the cavity, especially the septum, is the basis of the good results^[4].

The present surgical technique is quite similar to that which was described by the Caldeira & McCarthy^[5] technical report (no patch and two encircling sutures), retaining the Jatene “geometric preservation” principle and the “endoventricular suture and scar tissue exclusion” Dor principle. The technique details include: a) The entire operation is performed using a single suture tied after the two encircling stitches adjustments and at the final external suture; b) Before the second encircling “purse-string”, circular plication of the scar tissue is carried out, and; c) The final closure is completed by an invaginating suture that ensures improved hemostasis. Finally, it is emphasized that the no-patch surgi-

Table 1. Patient metadata of the ten operated patients.

Patient	Age	Gender	Thrombi	Myoc. Revasc.	IABP	Outcome	Funcional Class
1. CFC	69	Female	Yes	S-DP,M-LCX	Yes	4 days	Death
2. MSM	73	Female	Yes	-	Yes	7 months	Death
3. HM	58	Male	No	S-RCA, R-LCX, M-LDA	No	8 years	II
4. AL	56	Male	Yes	S-DP, S-DIAG, M-LDA	No	8 years	II
5. TGSS	49	Female	No	S-RCA, M-LDA	Yes	8 years	III
6. EZ	75	Male	No	S-DP, M-LDA	No	8 years	III
7. JT	62	Male	Yes	S-DP, M-LDA	No	6 years	I
8. MDE	69	Female	Yes	Mitral Prost., S-DP, S-LDA	Yes	15 days	Death
9. DQ	67	Female	Yes	S-LDA	No	5 years	I
10. STZ	74	Male	Yes	S-DP, S-LCX, M-LDA	No	5 years	I

S=Saphenous vein, M=Mammary artery; Prost=Prosthesis; Myoc. Revasc.=Myocardium Revascularization; LDA= Left descending artery; LCX=Left circumflex, Diag=diagonalis; DP=descending posterior; IABP=Intra-aortic balloon pump

Table 2. Echocardiography data of five patients two years after surgery.

Patient	Dimension LA (pre) mm	Dimension LA (post) mm	FLVDD (pre) mm	FLVDD (post) mm	LVMI (pre) mg/m ²	LVMI (post) mg/m ²	LVEF (pre) %	LVEF (post) %
1) STZ	50	52	62	52	103	87	30	34
2) DQ	46	45	45	47	118	83	25	50
3) HM	50	47	64	62	147	158	42	47
4) EZ	42	42	48	42	96	88	44	42
5) T	53	46	63	63	185	154	17	25

LA=Left atrium; FLVDD=Final left ventricle diastolic diameter; LVMI=Left ventricle mass index; LVEF=Left ventricle injection fraction

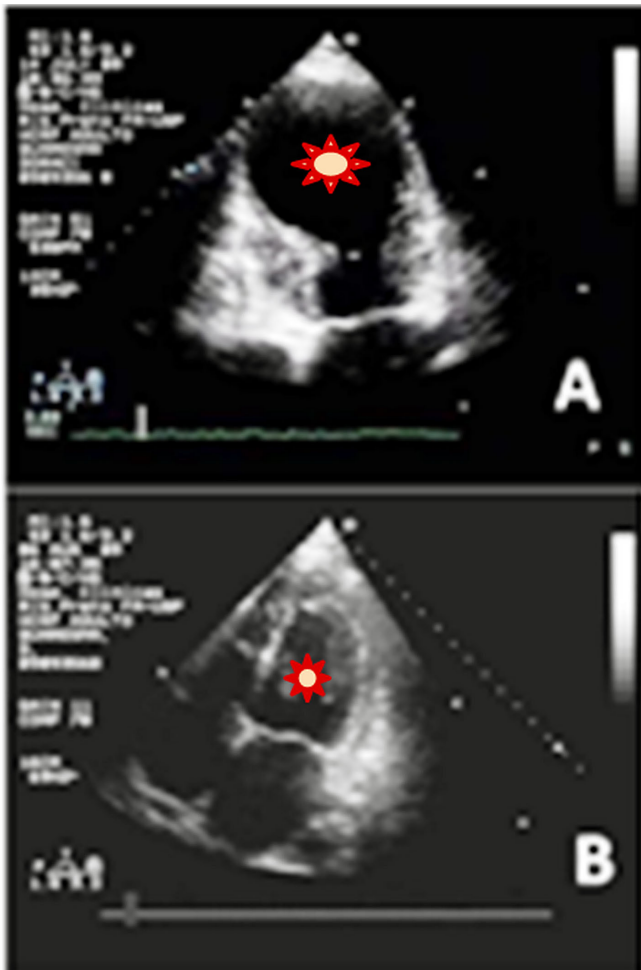


Fig. 2 - Echocardiogram. A) Presence of a large aneurysm of the left ventricular apex; B) Mild dilatation of the left atrium with other cardiac chambers of normal size. Note the postoperative elliptical shape of the left ventricle (2 years after surgery).

cal strategy has the indirect advantage of saving time since the stitches are performed in a continuous manner.

The surgical technique can also be considered a variant of the one proposed by Gomes et al.^[7,8] that also reported the unnecessary use of synthetic materials. This technique, with the elimination of prosthetic materials, virtually eliminates left ventricle akinetic areas and potentially attenuates chronic inflammatory reaction.

Based on superbly written opinion, Doenst^[1] theorized that left surgical ventricular reconstruction (SVR) approaches are “a matter of perspective”. According to the German author, the STICH trial (Surgical Treatment for IsChemic Heart failure) presented rather sobering information with its Hypothesis 2 outcome by demonstrating identical 5-year survival rates between SVR plus bypass grafting (CABG) and CABG alone. SVR also did not improve quality of life. This neutral finding spawned a series of critical responses with respect to trial design and conduct accompanied by appropriate responses by the trial’s leadership. At the end of this dispute, it appears that SVR has been accepted as not very useful for most patients and is less and less performed in daily practice. However, though SVR may be of low value for patients with dilated and massively remodeled ventricles, the surgery still bears therapeutic potential for some patients, for different reasons, so that the surgeon’s ability to perform this operation should not be lost^[1].

It is relevant to mention that there are, beside experiences around the world, convincing Brazilian experiences for ventricular reconstruction: 1) Direct suture^[9]; 2) Modification of the Cooley technique with patch suture^[10]; 3) Dor patch plasty with septal exclusion^[11-13]; 4) Jatene geometric reconstruction with semi-rigid bovine pericardial prosthesis^[14-17]; and 5) Attempts to compare different techniques without definitive proof of superiority among them^[18,19]. However, from the point of view of safety and reduction of surgical time, the “no patch” surgical variants techniques would be useful for the decision whether to operate left ventricular aneurysm or akinesia.

CONCLUSION

In conclusion, it is important to keep in mind that the data of this small number of patients who underwent the “no patch” left ventricle reconstruction variant was presented only to attest that the surgical technique is viable and safe. However, even considering these reasonable results, it remains hard to argue that this is a significant difference from other techniques. Moreover, one must take into account that surgical repair of aneurysms of the left ventricle is not the same for all patients since there are aneurysms with and without contractile lap, or even without lap, both accompanied by mitral regurgitation due to remodeling, consequent to the formation of ventricular aneurysm after acute myocardial infarction.

Authors' roles & responsibilities	
PRBE	Paper review, data, and writing
PVAT	Paper review and data
LGG	Paper review and data
LAJ	Paper review
CAF	Paper review
SB	Paper review
ACM	Paper review
AJR	Paper review and data
WVAV	Paper review and data

REFERENCES

1. Doenst T. Surgical approaches to left ventricular reconstruction: a matter of perspective. *Heart Fail Rev.* 2013;18(1):15-25.
2. Jatene AD. Left ventricular aneurysmectomy. Resection or reconstruction. *J Thorac Cardiovasc Surg.* 1985;89(3):321-31.
3. Dor V, Kreitmann P, Jourdan J. Interest of physiological closure (circumferential plasty on contractile areas) of left ventricle after resection and endocardectomy for aneurysm or akinetic zone. Comparison with classical technique about a series of 209 left ventricular resections. *J Cardiovasc Surg* 1985; 26:73 [abstract].
4. Dor V, Saab M, Coste P, Kornaszewska M, Montiglio F. Left ventricular aneurysm: a new surgical approach. *J Thorac Cardiovasc Surg.* 1989;37(1):11-9.
5. Caldeira C, McCarthy PM. A simple method of left ventricular reconstruction without patch for ischemic cardiomyopathy. *Ann Thorac Surg.* 2001;72(6):2148-9.
6. Evora PR, Bassetto S, Junior LA. A variant “no-patch” technique for surgery of left ventricular aneurysms. *Asian Cardiovasc Thorac Ann.* 2014;22(2):242-4.
7. Gomes WJ, Jaramillo JI, Asanuma F, Alves FA. Physiologic left ventricular reconstruction: the concept of maximum ventricular reduction and minimum inflammatory reaction. *Rev Bras Cir Cardiovasc.* 2004;19(4):353-7.
8. Gomes WJ, Saavedra RE, Maranhão DM, Carvalho AR, Alves FA. The renewed concept of the Batista operation for ischemic cardiomyopathy: maximum ventricular reduction. *Rev Bras Cir Cardiovasc.* 2011;26(4):544-51.
9. Kalil RK, Prates PR, Lucchese FA, Bertolotti VE, Nesralla IA. Resection of chronic aneurysms of the left ventricle post-myocardial infarct. *Arq Bras Cardiol.* 1977;30(1):37-42.
10. Prates PR, Vitola D, Sant’Anna JR, Lucchese FA, Kalil RA, Nesralla IA, et al. Modified Cooley technique for surgical repair of left ventricular aneurysms. *Arq Bras Cardiol.* 1991;56(3):219-22.
11. Almeida RMS, Lima Jr JD, Bastos LC, Carvalho CT, Loures DR. Remodelamento do ventrículo esquerdo pela técnica da endoventriculoplastia com exclusão septal: experiência inicial. *Rev Bras Cir Cardiovasc.* 2000;15(4):302-7.
12. Prates PR, Homs Neto A, Lovato LM, Teixeira GF, Sant’Anna JR, Yordi LM, et al. Late results of endoventricular patch plasty repair in akinetic and dyskinetic areas after acute myocardial infarction. *Arq Bras Cardiol.* 2002;79(2):107-16.
13. Almeida RM. Surgical reverse remodelling of the left ventricle: 111 months of follow-up. *Rev Bras Cir Cardiovasc.* 2009;24(4):470-7.
14. Braile DM, Mustafá RM, Santos JLV, Ardito RV, Zaiantchick M, Coelho WMC, et al. Correção da geometria do ventrículo esquerdo com prótese semi-rígida de pericárdio bovino. *Rev Bras Cir Cardiovasc.* 1991;6(2):109-15.
15. Branco JN, Buffolo E, Andrade JC, Succi JE, Leão LE, Biscegli JF, et al. Aneurysmectomy of the left ventricle. Geometric reconstruction using a semi-rigid teflon prosthesis. *Arq Bras Cardiol.* 1982;39(4):241-5.
16. Silveira WL, Leite AF, Soares EC, Nery MW, Carneiro AF, Oliveira VG. Short-term follow-up of patients after aneurysmectomy of the left ventricle. *Arq Bras Cardiol.* 2000;75(5):401-4.
17. Silveira Filho LM, Petrucci O, Vilarinho KAS, Baker RS, Garcia F, Oliveira PPM, et al. A bovine pericardium rigid prosthesis for left ventricle restoration: 12 years of follow-up. *Rev Bras Cir Cardiovasc.* 2011;26(2):164-72.
18. Borzellino DA, Puig LB, Martins SN, de Borzellino MR, Macruz H, de Oliveira SA, et al. Evaluation of the surgical treatment of left ventricular aneurysms. *Arq Bras Cardiol.* 1984;43(4):245-9.
19. Dancini JL, Rodrigues JJ, Santos J, Pinto RFA, Burgos FJC, Conforti CA. Aneurysmectomy do ventrículo esquerdo: avaliação tardia. *Rev Bras Cir Cardiovasc.* 1996;11(1):23-9.