

# Technical option on tetralogy of Fallot with abnormal coronary artery. Cases report

*Opção técnica na tetralogia de Fallot com artéria coronária anômala. Relato de casos*

Claudio Roberto ASSUMPÇÃO<sup>1</sup>, João de Deus e BRITO<sup>2</sup>, Eulália PFEIFER<sup>3</sup>, Lilian STEWART<sup>4</sup>, Antonio de Pádua JAZBIK<sup>5</sup>

RBCCV 44205-985

## **Abstract**

Report on two children, one 11 year-male and a year-six-month-female with tetralogy of Fallot (TF) associated with anomalous origin of coronary artery crossing the right ventricle outlet tract (RVOT). Diagnosis was done by echocardiography and cardiac catheterization. During surgical correction, we used an external composite tubular pericardium bovine graft and posterior wall of the pulmonary artery between the right ventricle and the pulmonary artery trunk. Patients had an uneventful post-operative period and were discharged asymptomatic. It is more an option on correction of TF with anomalous coronary artery.

**Descriptors:** Tetralogy of Fallot/surgery. Heart defects, congenital, surgery. Coronary vessel anomalies/surgery.

## **Resumo**

Relatamos dois casos um menino de 11 anos e uma menina de um ano e seis meses, portadores de tetralogia de Fallot com artéria coronária de origem anômala, cruzando a via de saída de ventrículo direito. O diagnóstico foi feito com ecocardiografia e cateterismo cardíaco. Utilizamos, na correção, um enxerto externo composto de pericárdio bovino e parede posterior da artéria pulmonar, entre o ventrículo direito e o tronco da artéria pulmonar. As crianças tiveram boa evolução pós-operatória, obtendo alta hospitalar assintomáticas. É mais uma opção técnica na correção da tetralogia de Fallot com artéria coronária anômala.

**Descritores:** Tetralogia de Fallot/cirurgia. Cardiopatias congênitas, cirurgia. Anomalias dos vasos coronários/cirurgia.

1. Cardiovascular surgeon. Head of the Cardiac Surgery of the Aloysio de Castro State Institute of Cardiology, Rio de Janeiro
2. Full Professor of the Faculty of Medicine of the UFRJ (Professor of the Souza Marques Medical School – RJ)
3. Head of the Cardiac Surgery of the Cardiac Surgery of the Aloysio de Castro State Institute of Cardiology, Rio de Janeiro
4. Head of the Cardiopediatric Service of the Cardiac Surgery of the Aloysio de Castro State Institute of Cardiology, Rio de Janeiro
5. Head of the Cardiopediatric Postoperative Division of the Aloysio de Castro State Institute of Cardiology

This study was carried out at the Cardiac Surgery of the Aloysio de Castro State Institute of Cardiology, Rio de Janeiro.

Address for correspondence:

Claudio Roberto Assumpção. Rua David Campista, 326 Botafogo. CEP: 22261-010 - Rio de Janeiro, RJ.

E-mail address: claudior@cardiol.br

Article received on November 2<sup>nd</sup>, 2007

Article accepted on April 17<sup>th</sup>, 2008

## INTRODUCTION

A coronary artery with an abnormal pathway crossing the right ventricle outflow tract represents a challenge for the surgeons. This rare anomaly inspired the use of different techniques, which have been reported either in the reconstruction of the outlet chamber of the right ventricle (RV) (by graft or external conducts [1-2]) or in the correction by transatrial and transpulmonary surgical approach [3]. In the two cases presented herein, we reproduced a technique that was successfully performed by van Son in 1995 [1] and by Dandolu et al in 1998 [4].

In this technique, we built two right ventricle outflow tracts. The first was composed of an external biological conduct (between the right ventricle and the pulmonary artery trunk on the coronary artery); the second maintained the original outflow tract of the pulmonary artery. Thus, these two outflow tracts compose a blood flow without any obstruction from the right ventricle to the pulmonary artery trunk. In this report, we describe the used surgical technique and the obtained outcomes. It is important to emphasize that this technical possibility may be one of the alternatives in the correction of Tetralogy of Fallot with abnormal coronary artery.

## METHODS

Between 2001 and 2007, in the Aloysio de Castro State Institute of Cardiology in Rio de Janeiro, 568 children underwent heart surgery for treatment of congenital heart disease. In this group of patients, 55 presented Tetralogy of Fallot, from which 53 have been corrected using the transventricular approach after closing the interventricular septum defect with the transatrial approach. In two children who presented abnormal coronary artery crossing the RVOT, we used the technical option, which will be described in the report of these two cases.

This study was approved by the Research Ethics Committee of the Aloysio de Castro State Institute of Cardiology under the number 2008/16 of 03/05/2008.

## CASE REPORT 1

11-year-old boy was referred to the Cardiopediatric Department with diagnosis of Tetralogy of Fallot. The patient presented cyanosis from the first days of life and fatigue after moderate and slight efforts. During the clinical examination, he was extremely cyanotic; dyspnea at rest, with reduced height and weight for his age, as well as digital clubbing. During auscultation an ejective murmur in left sternal margin was audible, +++++/ 6. Chest radiography showed an increase of the right cavities. The hematocrit at the time of admission at hospital was 75% with the need for

a transfusion. Preoperative echocardiography: wide interventricular septal defect. Presence of abnormal coronary artery. The cardiac catheterization showed subvalve stenosis and pulmonary ring with fair diameter. There was a single coronary artery trunk with anterior interventricular coronary artery crossing the right ventricle outflow tract. The patient underwent surgery on 02/27/02.

## Surgical technique

After transsternal median thoracotomy and longitudinal pericardiotomy, an increase of the right cavities was found. The coronary arteries and veins were dilated and there was large epicardial collateral circulation. Important coronary branch crossed the right ventricle outflow tract. The ring and trunk of the pulmonary artery had appropriate dimensions. Isolation of ascending aorta. Purse suturing in the ascending aorta, superior vena cava, right atrium (near the inferior cava) and right superior pulmonary vein for drainage of the left ventricle. Systemic heparinization with 400 U/kg of pharmacological agent and initiation of cardiopulmonary bypass. Venous drainage of two cavas and left cavities through the right superior pulmonary vein with placement of the catheter tip in the left ventricle. Arterial return performed through the ascending aorta.

Once a temperature of 32° Celsius reached, the aorta was occluded with special forceps. Hypothermic blood cardioplegic solution was infused in the ascending aorta over 3 minutes and repeated at every 20 minutes of anoxic arrest. During cardiac arrest, a longitudinal opening of the right atrium was performed. There was small foramen ovale, which was closed with a x-stitch, 4-0 monofilament. Through the tricuspid valve a large defect in the interventricular septum was noted, (with two centimeters in the largest axis). The defect was closed with a heterologous bovine pericardium graft with one part attached with interrupted U sutures anchored in Teflon tablets, and other part attached with continuous suture 4-0 monofilament. Right atrium closing with double suture 4-0 monofilament. Incision of two centimeters in the right ventricular infundibulum, perpendicular and caudal to the coronary branch with the abnormal pathway.

There was severe hypertrophy of the parietal and septal extensions of the septomarginal trabeculae, covered by fibrous tissue, which created the "infundibuli" with a maximum 0,6cm diameter that was partially resected. The pulmonary valve was slightly thickened, but without stenosis. The valvar ring presented compatible dimensions allowing the access of Hegar's dilator of 14mm. The anterior wall of the pulmonary artery trunk was longitudinally sectioned as a flap and reversaly sutured on the abnormal coronary in the upper extremity of the RV incision.

In order to fill the anterior wall of this new conduct, a patch of bovine pericardium was sutured in a tile shape on

the edges of the pulmonary artery trunk and the remainder of the ventricle incision (Figure 1). The occlusion forceps of the aorta was removed after the patient was warmed, and after the careful removal of the air inside the left cavities. The heart spontaneously started to beat again, initially separated, and then reached sinus rhythm. CPB suspension at 37° Celsius. Volemic replacement based on right atrium pressure. Hemostasis review. Temporary pacemaker wire was installed in the RV wall. Drainage of the mediastinum and closing of the chest by planes.

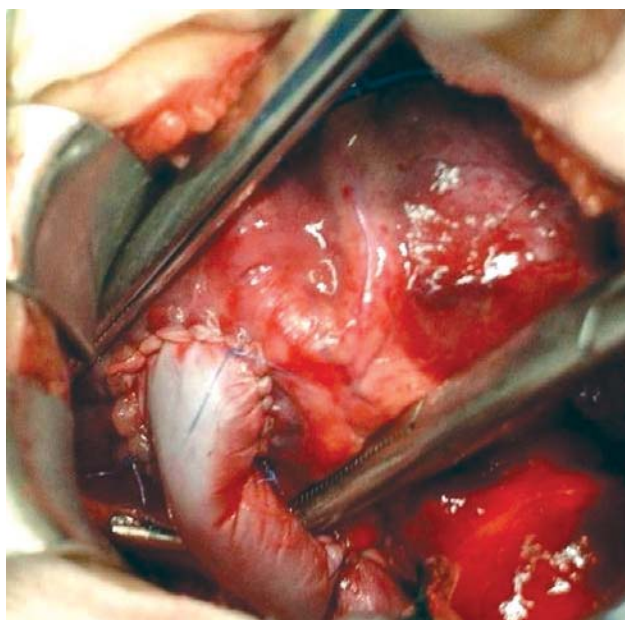


Fig. 1 – Extracardiac conduct – Biological graft filled between the right ventricle and the pulmonary artery trunk upon the abnormal coronary.

The patient presented slight right heart failure and pericardial effusion in the immediate postoperative period. He improved with clinical treatment and pericardial drainage. The patient had an uneventful postoperative course and was discharged from hospital asymptomatic. ECO (postoperative recording - tape 65), closed interventricular septal defect without residual shunt, two patent RV outflow tracts with gradient of 40mmHg. Slight pulmonary valve insufficiency.

#### Evolution

The patient developed uneventfully and was discharged from hospital asymptomatic. In November 2007, at 16 years old, the patient was well and without complaints. Transthoracic echocardiography was performed:

LV: Normal function with EF of 80%

RV: Normal function, with slight dilation and pulmonary ring of 1,87cm.

Moderate tricuspid and pulmonary insufficiency;

Moderate pulmonary stenosis and;  
Right ventricle with two outflow tracts.

#### CASE REPORT 2

An 18-month-old girl was admitted for cardiopediatric follow-up and correction of Tetralogy of Fallot. Her mother reported that, since the first month of life, the patient presented cyanotic mucous, and at six months began to present cyanotic crisis. The patient was then treated with beta blocker. The mother also reported neurological follow-up of the patient and an implant of a ventriculoperitoneal valve for the treatment of hydrocephaly. During clinical examination, the patient presented moderate cyanosis, without dyspnea, palpable and symmetrical pulses, without edema. ECG: RV hypertrophy. Cardiac auscultation with regular rhythm in two clicks, systolic murmur ++++/6 in left sternal margin. Ecocardiography: wide interventricular communication, anterior deviation of the infundibular-valvular pulmonary stenosis. The images suggested single coronary ostium.

The cardiac catheterization confirmed the diagnosis of Tetralogy of Fallot with a single coronary trunk. A branch of the right coronary artery gave origin of an important coronary artery branch, crossing the RV anterior wall. Hypertrophic right ventricle with good function, wide interventricular septal defect with dextroposition of the aorta above 50%. Undergone surgical correction on 29/10/03.

#### Surgical technique

Aside from the need for pulmonary commissurotomy to treat valve stenosis, and the 1,5cm incision in the RV wall, the technical procedure was similar to that which was previously reported in case 1.

The patient developed uneventfully in the immediate postoperative, with slight right heart failure that improved with clinical treatment. Echocardiography was performed in the immediate postoperative period: two patent RV outflow tracts without significant pressure gradient, mild pulmonary regurgitation and good ventricular function. Absence of residual shunt. Hospital discharge without cardiovascular symptoms.

#### Evolution

After surgery, the child's cardiovascular development was uneventful until four years and two months of age, at which point she died due to neurological disease with hydrocephaly, which she already presented before correction of Tetralogy of Fallot.

#### DISCUSSION

The most common anatomical variation occurs when the anterior descending artery is directly originated from

the right coronary artery [5]. Less often, the coronary artery is single, or the right coronary artery originates from the circumflex coronary artery [5]. In another variation, the septal coronary arteries originate from the left and right coronary arteries [6]. The alternative procedure reported in these two cases is similar to a technique that has been previously described [1,4]. In this technique, the authors adjusted the procedure described by Barbero-Marcial et al. for correction of *truncus arteriosus* types I and II [7], and they used it analogously for the surgical treatment of Tetralogy of Fallot with abnormal coronary artery [1].

Because the posterior pulmonary artery wall of the patient is used in making composed biological conduct (either made of bovine pericardium with cryopreserved pulmonary graft [4]), it is natural that the biological conduct presents a real potential for growth over the years. [1]. This technique, in addition to the transannular patch, undoubtedly causes pulmonary failure [4]. However, the pulmonary failure (which resulted from a valveless graft) may be avoided using a monocuspid valve on the anterior wall of the bovine pericardium graft [7]). And, to avoid early calcification, Croti and Barbero Marcial employ porcine monocuspid for surgical correction of pulmonary atresia with interventricular communication [8]. On the other hand, residual stenosis may occur and must be subsequently treated [4].

#### CONCLUSION

The technique reported in this study proved to be safe and effective. We recommend it as another option to be employed in the correction of Tetralogy of Fallot with abnormal coronary artery that crosses the RVOT.

#### REFERENCES

1. van Son JA. Repair of tetralogy of Fallot with anomalous origin of left anterior descending coronary artery. *J Thorac Cardiovasc Surg.* 1995;110(2):561-2.
2. Bonchek LI. A method of outflow tract reconstruction in tetralogy of Fallot with anomalous anterior descending coronary artery. *Ann Thorac Surg.* 1976;21(5):451-3.
3. Pacifico AD, Sand ME, Barger LM Jr, Colvin EC. Transatrial-transpulmonary repair of tetralogy of Fallot. *J Thorac Cardiovasc Surg.* 1987;93(6):919-24.
4. Dandolu BR, Baldwin HS, Norwood WI Jr, Jacobs ML. Tetralogy of Fallot with anomalous coronary artery: double outflow technique. *Ann Thorac Surg.* 1999;67(4):1178-80.
5. Tchervenkov CI, Pelletier MP, Shum-Tim D, Béland MJ, Rohlicek C. Primary repair minimizing the use of conduits in neonates and infants with tetralogy or double-outlet right ventricle and anomalous coronary arteries. *J Thorac Cardiovasc Surg.* 2000;119(2):314-23.
6. Dabizzi RP, Caprioli G, Aiazzi L. Distribution and anomalies of coronary arteries in tetralogy of fallot. *Circulation.* 1980;61(1):95-102.
7. Barbero-Marcial M, Riso A, Atik E, Jatene A. A technique for correction of truncus arteriosus types I and II without extracardiac conduits. *J Thorac Cardiovasc Surg.* 1990;99(2):364-9.
8. Croti UA, Barbero-Marcial M, Jatene MB, Riso AA, Tanamati C, Aiello VD, et al. Classificação anatômica e correção cirúrgica da atresia pulmonar com comunicação interventricular. *Rev Bras Cir Cardiovasc.* 2001;16(4):321-36.