

Operative treatment after iatrogenic left main dissection

Tratamento operatório da dissecação iatrogênica do tronco de coronária esquerda

João Roberto BREDA¹, Ana Silvia Castaldi Ragnognetti BREDA², Adilson Casemiro PIRES³

RBCCV 44205-984

Abstract

Coronary dissection has a significant morbidity and mortality. The ideal management of acute coronary occlusion is the prompt restoration of the vessel patency to limit the extent and duration of ischemia. In the setting of dissection during percutaneous procedure, the usual approach has been emergency aortocoronary bypass surgery. The authors present a case of a patient with left main dissection during percutaneous transluminal coronary angioplasty. This problem was successfully managed with emergent aortocoronary bypass surgery.

Descriptors: Angioplasty transluminal percutaneous coronary/adverse effects. Coronary vessels/injuries. Iatronic disease. Catheterization.

Resumo

A dissecação coronária iatrogênica apresenta alta morbidade e mortalidade. Diante da oclusão aguda do fluxo coronariano, é fundamental a restauração imediata da perviabilidade do vaso para limitar a extensão e duração da isquemia. Nesta situação, pode estar indicada a revascularização cirúrgica do miocárdio de emergência. Os autores apresentam caso de um paciente com dissecação iatrogênica do tronco de coronária esquerda durante angioplastia transluminal percutânea, que foi solucionada pela realização de revascularização completa do miocárdio, com resultado satisfatório.

Descritores: Angioplastia coronária transluminal percutânea, efeitos adversos. Vasos coronários/lesões. Doença iatrogênica. Cateterismo.

1. Doctorate degree (collaborator professor)
2. Cardiology Specialist (cardiologist)
3. Doctorate degree (full professor)

This study was carried out at the Faculdade de Medicina da Fundação do ABC; Discipline of Cardiovascular Surgery.

Correspondence address:

João Roberto Breda. Rua Antonio Bastos, 755 - Apto. 31. Santo André/SP. CEP: 09040-220. Tel: (11) 4438-4311.
E-mail: jrbreda@hotmail.com.br.

Article received on January 3rd, 2008
Article accepted on April 18th, 2008

INTRODUCTION

The occurrence of iatrogenic coronary dissection represents an entity of high morbidity and mortality. Angiographic quantitative and qualitative analysis of coronary lesions after percutaneous angioplasty showed an occurrence of dissection in 20% to 40% of the patients undergoing the procedure. However, when the lesion to the intima is small, it is observed a favorable clinical course, but larger and more complex lesions can cause acute occlusion of the coronary artery, leading to severe clinical repercussion to the patient [1].

Emergency coronary artery bypass grafting (CABG) after percutaneous angioplasty failure presents mortality rate ranging from 4% to 14% [2].

The aim of the present study is to report a case of left main coronary artery dissection after left marginal artery percutaneous transluminal coronary angioplasty (PTCA), which has evolved to acute coronary artery occlusion, requiring emergency CABG surgery.

CASEREPORT

A 68-year-old male hypertensive and dyslipidemic patient was referred to the Cardiology Service due to Chronic Coronary Insufficiency (CCI) diagnosed clinically and confirmed through cineangiocoronariography and ventriculography. The patient was sedated, with stable angina CCS II (Canadian Cardiovascular Society – CCS), and under optimal drug therapy.

The angiographic study evidenced a circumflex artery moderately developed and totally occluded after giving rise to the left marginal artery. This marginal artery presented with segmental proximal lesion which was occluding 80% of the artery lumen. The other coronary arteries did not present with severely obstructive lesions (Figure 1). Left ventriculography showed enlarged diastolic and systolic volumes with a significant overall contractility deficit due to severe diffuse hypokinesia.

The case was submitted to a consultation by both reference cardiologist and hemodynamic staff. Left marginal artery percutaneous transluminal coronary angioplasty was the procedure of choice, with stent implantation and balloon dilation of the circumflex artery. The left marginal artery procedure final aspect showed a patent artery with a TIMI III flow without dissection image and no residual lesion with an expanded stent. After the circumflex artery dilation, the control angiography evidenced a dissection image at the left main coronary artery, which evolved retrogradely, thus jeopardizing the flow to both the anterior interventricular branch and the circumflex artery itself (Figure 2).

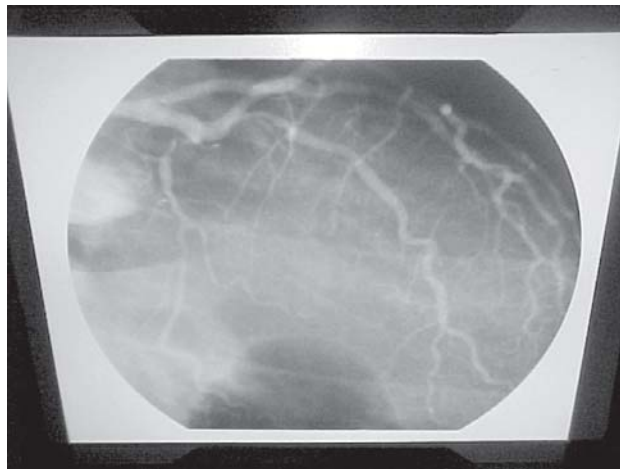


Fig. 1 - Cineangiocoronariography highlighting total occlusion of both circumflex artery and left artery proximal lesion

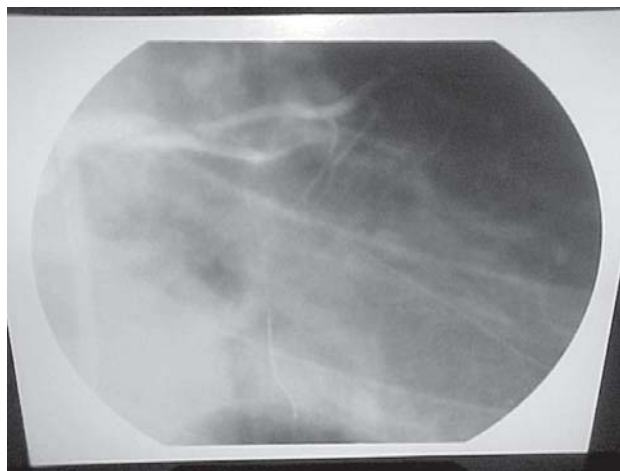


Fig. 2 – Left main coronary artery dissection

The patient presented a cardiorespiratory arrest at the hemodynamic room. Usual resuscitation maneuvers were promptly initiated with orotracheal intubation, drug administration, and external heart massage. A clinical picture reversal occurred and the patient was taken to the operating room to have an emergency CABG surgery performed.

Operative technique

The surgery was initiated with invasive hemodynamic monitoring with following parameters measured: mean arterial pressure, venous central pressure, and urine output, besides respiratory monitoring through pulse oximetry and electrode placement for intraaortic balloon.

Just after a median sternotomy was performed, cardiopulmonary bypass support was established via ascending aorta and inferior vena cava cannulation, while

the saphenous vein segment to be used as grafting was being chosen. Myocardial protection was achieved by controlled hypoxia through intermittent aortic cross clamping; the saphenous vein and aorta segments were grafted to the following coronary arteries: the anterior interventricular branch, diagonal artery, and left marginal artery of the circumflex artery. The cardiopulmonary bypass withdrawal was possible with the aid of vasoactive drugs inotropic support (dobutamine and noradrenaline); mechanical support with intraaortic balloon implantation was not required.

On the completion of surgery, the patient at normothermia was taken to the Postoperative Unit where he was continuously monitored. During the postoperative period, alterations in ST segment elevation or depression, or new Q waves on electrocardiogram were not identified. The behavior of the enzymatic curve was considered normal for the postoperative CABG surgery period, and it did not suggest an occurrence of perioperative acute myocardial infarction.

There was no complicated in-hospital or intraoperative course, and the patient was discharged from the hospital in good health condition on the postoperative day 8.

DISCUSSION

Percutaneous transluminal coronary angioplasty complications can occur in 21% of the patients undergoing the surgical procedure. The compromised arterial flow is considered the major complication, and it occurs as a consequence of intracoronary thrombosis, atheroma plaque displacement, spasm, or artery dissection. Dissection of the coronary artery after angioplasty usually involves the right coronary artery (67% of the cases) and its precise mechanism is not completely cleared yet, although the atheromatous degree and the type of catheter used are two factors of the most relevant importance involved in this complication. At times, this severe condition has been resolved in the hemodynamic room itself, using a stent implanted at the arterial dissection site. This procedure has become important in the extent that it can allow the coronary artery flow to be re-established, acting as a definite treatment or as a bridge to CABG surgical treatment [3].

The incidence of emergency heart surgery after coronary angioplasty can vary from 2% to 5%. Although there is a trend towards the reduction of the event complications related to the procedure, in-hospital mortality is higher in individuals undergoing emergency CABG. This increased in-hospital mortality is not associated to preangioplasty factors, but to the unstable conditions in which the patients are sent to the operating room [4].

Reinecke et al, analyzing the differences between

survivors and nonsurvivors of emergency CABG after angioplasty, have identified as a factor of increasing chance of success the following: young age (58.2 vs 65.4 years, $p<0.01$), larger body surface (1.93 vs 1.73 m², $p<0.01$) complete operative myocardial revascularization (80% vs 36%, $p.01$), and lower cardiopulmonary bypass (CPB) time (56 vs 91 minutes, $p<0.01$). In the current study, the majority of nonsurvivors were females, with severely depressed ventricular function and requiring intensive treatment (heart massage, ventricular defibrillation, vasoactive drugs, and intraaortic balloon implantation) [5].

The aims of emergency CABG in dissecting the left main coronary artery are as follows: a) to re-establish blood flow compromised by dissection, b) to avoid the dissection development course, and c) to preserve ventricular function.

In the patient of the present case report, due to the hemodynamic instability and to the presence of severe ischemia observed on surface electrocardiogram at the operating room arrival, it was decided not to use the left internal thoracic artery (LITA) grafting, performing the prompt establishment of CPB support and the complete revascularization of the coronary segments involved in the dissection.

Regarding the indication for a percutaneous procedure, the North American Guidelines published in 2001 recommend as class III (contraindication): cases involving small areas of the viable myocardium at risk with no objective evidences of ischemia; lesions with poor angiographic appearance; atypical symptoms not suggesting ischemia; target lesions smaller than 50%, and high-risk situations (left main coronary artery unprotected lesion treatment) [6]. Moreover, recent studies have provided statistical support for using optimal medical therapy associated to lifestyle changes, with outcomes that overlap those accomplished with less invasive therapy regarding patients with stable coronary artery disease [7].

Thus, despite the severity of this situation, which is associated to a higher morbimortality rate, the emergency surgical therapy through complete revascularization of the coronary arteries involved in the dissection, presented a satisfactory outcome with uncomplicated in-hospital course favorable to the patient of this case report.

REFERENCES

1. Hermans WR, Foley DP, Rensing BJ, Rutsch W, Heyndrickx GR, Danchin N, et al. Usefulness of quantitative and qualitative angiographic lesion morphology, and clinical characteristics in

-
- predicting major adverse cardiac events during and after native coronary ballon angioplasty. CARPORT and MERCATOR Study Groups. *Am J Cardiol.* 1993;72(1):14-20.
2. Barakate MS, Bannon PG, Hughes CF, Horton MD, Callaway A, Hurst T. Emergency surgery after unsuccessful coronary angioplasty: a review of 15 years' experience. *Ann Thorac Surg.* 2003;75(5):1400-5.
 3. Copini RT, Alves CM, Costa FA, Souza JA, Herrmann JL. Utilização de "stent" para tratamento da dissecção coronária iatrogênica. *Arq Bras Cardiol.* 1998;70(1):55-7.
 4. Boylan MJ, Lytle BW, Taylor PC, Loop FD, Proudfit W, Borsh JA, et al. Have PTCA failures requiring emergent bypass operation changed? *Ann Thorac Surg.* 1995;59(2):283-6.
 5. Reinecke H, Fetsch T, Roeder N, Schmid C, Winter A, Ribbing M, et al. Emergency coronary artery bypass grafting after failed coronary angioplasty: what has changed in a decade? *Ann Thorac Surg.* 2000;70(6):1997-2003.
 6. King SB 3rd, Smith SC Jr, Hirshfeld JW Jr, Jacobs AK, Morrison DA, Williams DO; et al. 2007 Focused Updated of the ACC/AHA/SCAI 2005 Guideline Update for Percutaneous Coronary Intervention: a report of the American College of Cardiology/American Heart Association Task Force on Practice Guidelines: 2007 Writing Group to Review New Evidence and Update the ACC/AHA/SCAI 2005 Guideline Update for Percutaneous Coronary Intervention, Writing on Behalf of the 2005 Writing Committee. *Circulation.* 2008; 117(2):261-95.
 7. Boden WE, O'Rourke RA, Teo KK, Hartigan PM, Maron DJ, Kostuk WJ, et al. Optimal medical therapy with or without PCI for stable coronary disease. *N Engl J Med.* 2007;356(15):1503-16.