

Aortic arch surgery with bilateral cerebral perfusion by isolation of brachiocephalic trunk and left carotid artery

Cirurgia do arco aórtico com perfusão cerebral bilateral pelo isolamento do tronco braquiocefálico e da artéria carótida esquerda

Valdo José CARREIRA¹, Denoel Marcelino de OLIVEIRA², Júlio Faria HONÓRIO³, Ivo Thadeu de Freitas PINHEIRO⁴, Ezequiel Moisés CHISSONDE⁵, Renato Max FARIA⁶

RBCCV 44205-952

Abstract

Objective: To evaluate the results of a technique described by Carreira et al. using bilateral antegrade selective cerebral perfusion by isolating the brachiocephalic trunk and the left carotid artery.

Methods: Fifteen patients were operated between June 2005 and September 2007. Data analysis were performed using Epi Info and statistical significance was set at $p < 0.05$.

Results: Of the 15 patients, 53.3% were male; mean age was 59.86 ± 15.4 years; 60% presented with type A acute aortic dissection; 6.7% type B; and 33.3% aneurysm of aorta and arch. Mean CPB and aortic clamping time was 177.6 ± 39.4 and 135.9 ± 34.0 minutes, respectively. In this group, 86.7% were not submitted to total circulatory arrest, with mean unilateral and bilateral selective cerebral perfusion time of 10.9 ± 2.0 and 57.2 ± 21.2 minutes, respectively. Mean hypothermic temperature was $23.0 \pm 2.9^\circ\text{C}$. Two had left

subclavian artery ligation, 60% used separated aortic grafts, and four used aortic endoprosthesis. Three (20%) patients died, all of them in the acute aortic dissection group. There were no neurological complications. The mean follow up time was 11.7 ± 9.6 months. Regarding mortality, none of the parameters were statistically significant ($p > 0.05$).

Conclusion: The technique of bilateral selective cerebral perfusion described by Carreira et al. can be performed by others and presents similar results to the international literature. The excellent neurological outcome and easy bleeding control on surgical sutures lines are the major advantages of this new procedure.

Descriptors: Cardiac surgical procedures. Hypothermia. Thoracic aorta/surgery. Aortic aneurysm. Brachiocephalic trunk. Carotid arteries.

1. Specialist by BSCVS/SBCCV; Head of Cardiovascular Surgery Service; Hospital Barra D'or and Casa de Saúde São José.
2. Master degree in cardiovascular surgery; Surgeon; Rede D'or de Hospitais, Casa de Saúde São José and Instituto Nacional de Cardiologia Laranjeiras.
3. Specialist by BSCVS/SBCCV Surgeon; Rede D'or de Hospitais, Casa de Saúde São José.
4. Specialist by Brazilian Society of Anesthesiology (SBA); Anesthesiologist; Rede D'or de Hospitais and Casa de Saúde São José.
5. Resident Physician; Cardiovascular Surgery.
6. Medical Student.

This study was carried out at Rede D'or de Hospitais, Casa de Saúde São José, Hospital Samaritano, Rio de Janeiro, RJ, Brazil.

Correspondence address: Valdo José Carreira.
Av. Canal de Marapendi, 2915/102 bloco 3 - Barra da Tijuca - Rio de Janeiro - RJ - Brasil - CEP: 22631-050.
E-mail: vcarreira@cardiol.br

Article received on: November 11th, 2007
Article accepted on: March 10th, 2008

Resumo

Objetivo: Estudar os resultados da técnica descrita por Carreira et al. com utilização de perfusão cerebral seletiva bilateral (PCSAB) pelo isolamento do tronco braquiocefálico e artéria carótida esquerda.

Métodos: Quinze pacientes foram operados consecutivamente entre de junho de 2005 e setembro de 2007. Os dados foram analisados por programa informatizado Epi Info e significância estatística com $p < 0,05$.

Resultados: No grupo analisado, 53,3% dos pacientes eram do sexo masculino e a idade média era de $59,86 \pm 15,4$ anos. Com relação à doença de base, 60% dos pacientes apresentavam dissecação aguda do tipo A, 6,7% tipo B e 33,3% aneurisma da aorta e arco. O tempo médio de CEC e de anoxia foi de $177,6 \pm 39,4$ e $135,9 \pm 34,0$ minutos, respectivamente. Nesse grupo, 86,7% dos pacientes não foram submetidos a parada circulatória total, com tempo médio de PCSA unilateral e bilateral de $10,9 \pm 2,0$ e $57,2 \pm 21,2$ minutos, respectivamente. A temperatura média da

hipotermia foi de $23,0 \pm 2,9^\circ\text{C}$. A artéria subclávia esquerda foi ligada em dois (13,3%) pacientes, e nove (60%) foram submetidos a anastomoses proximal e distal com tubos separados. Utilizou-se endoprótese vascular na aorta descendente em quatro (26,7%) pacientes. Três (20%) pacientes morreram, todos do subgrupo de dissecação aguda. Nenhum dos sobreviventes apresentou seqüelas neurológicas, com média de acompanhamento tardio de $11,7 \pm 9,6$ meses. Nenhum dos fatores estudados apresentou relação estatisticamente significativa com a mortalidade ($p > 0,05$).

Conclusão: A técnica de PCSAB é reprodutível e apresenta resultados semelhantes aos da literatura mundial. A excelente evolução neurológica e o fácil controle de sangramentos nas linhas de sutura podem ter contribuído com os resultados obtidos.

Descritores: Procedimentos cirúrgicos cardíacos. Hipotermia. Aorta torácica/cirurgia. Aneurisma aórtico. Tronco braquiocefálico. Artérias carótidas.

INTRODUCTION

Surgeries involving the aortic arch still present high rates of hemorrhagic and neurologic complications. These complications are mainly related with the complexity of surgical repairs and the use of deep hypothermia with total circulatory arrest.

Circulatory arrest with deep hypothermia with temperature varying from 15°C to 18°C is use alone or together with cerebral perfusion techniques for intraoperative protection of central nervous system [1]. Several techniques, including deep hypothermia with total circulatory arrest (DHTCA) [2-4], unilateral or bilateral selective antegrade cerebral perfusion (SACP) [5-7], and retrograde cerebral perfusion (RCP) through superior vena cava [8-10] have been used to protect the central nervous system. Each one of these techniques presents advantages and disadvantages and their different cannulation forms have recently been revised by Dias et al. [11].

Coselli et al. [12] reported that patients using deep hypothermia with total circulatory arrest had lower mortality rate (7.9) and stroke (2.4) if in comparison to the patients who did not use deep hypothermia during circulatory arrest (mortality, 14.8; stroke, 6.5). Safi et al. [13] demonstrated that the use of deep hypothermia with total circulatory arrest has a protective effect against stroke (3) if compared with no deep hypothermia with total circulatory arrest (9%).

Okita et al. [14] carried out a prospective study regarding brain protection during aortic arch surgeries comparing deep hypothermia with total circulatory arrest and retrograde cerebral perfusion versus selective antegrade cerebral perfusion. The y

demonstrated that both methods of brain protection resulted in acceptable mortality and morbidity rates. However, transient brain dysfunction prevalence was significantly higher in patients receiving retrograde cerebral perfusion.

The greatest advantage of selective cerebral perfusion (SCP) lies on the possibility of repairing the aortic arch over an extended period of time, once the brain will be continuously perfused. However, some criticisms to this method are pointed out, such as embolism resulting from cannulation, 4.8% during cross-clamping and 0.6% during selective cerebral perfusion, and due to the anatomical variation of intracranial blood flow. Using selective cerebral reperfusion in 60 patients with aortic arch aneurysm, Ohmi et al. [15] reported higher postoperative stroke prevalence in patients with occlusive arterial disease, especially in emergency cases in which brain circulation is unknown.

Merkkola et al. [16] carried out an anatomic study to assess cerebral perfusion and uniform distribution of blood to both hemispheres of the brain through the circle of Willis in patients receiving right axillary artery cannulation. The outcomes show that 22% of the anterior communicating arteries and 46% of the left posterior communicating arteries were missing. In this anatomic population the perfusion to the left hemisphere might have been insufficient in 14% to 17% of the patients.

Many groups have shown good outcomes with varied types of bilateral cerebral perfusion. Bachet et al. [17] used bilateral carotid artery cannulation and perfusion with cooled at 6°C to 12°C , while the body temperature was maintained at moderate hypothermia (25°C to 28°C). To perform the open distal repair, the cardiopulmonary bypass is discontinued

while the carotid perfusion is maintained (250 mL/min to 350 mL/min). Kazui et al. [18] described a technique for bilateral antegrade selective cerebral perfusion through cannulation of the brachiocephalic trunk and the left common carotid artery, using a 15Fr-retrograde perfusion cannula of coronary sinus with a manually-inflatable balloon. Kurisu et al. [19] used antegrade selective cerebral perfusion established by vascular grafts anastomosed to the bilateral axillary arteries and a perfusion catheter placed directly into the left carotid artery. Minatoya et al. [20] reported the use of antegrade selective cerebral perfusion for brain protection in the reconstruction of the arch using independent perfusion from arch vessels by using quadrifurcated grafts. Spielvogel et al. [21] described the use of a trifurcated graft to isolated anastomoses of arch vessels, however, the cannulation for cardiopulmonary bypass was performed through right axillary artery with deep hypothermia at 15°C. Recently, this same group has reported the outcomes of 15 patients operated on with a mortality rate of 4.6% and permanent stroke of 4% [22].

All these groups have shown good outcomes, however, with complex approaches to achieve bilateral cerebral perfusion and some of them requiring periods with no brain blood flow. The technique previously described by Carreira et al. [23] allows performing a more rapid preparation for bilateral antegrade cerebral perfusion with no interruption of brain blood flow, using of higher levels of temperature during hypothermia besides allowing the easily repair of possible surgical bleeding. The aim of the present study is to assess aortic arch surgery outcomes using the technique previously mentioned.

METHODS

Demographic, clinical, operative, and postoperative data of 15 consecutive patients operated on between July 2005 and September 2007. The study was approved by the appropriate Ethics Committee for each participant institution.

These patients presented with aortic diseases affecting the aortic arch. Patients were operated on with the use of bilateral selective cerebral perfusion by isolating the brachiocephalic trunk and left carotid artery, a technique which has already been described [23].

Data were analyzed by the statistical computer software Epi Info 6.02. We considered $p < 0.05$ as significant.

Surgical technique

A median sternotomy was performed to access the heart and the great vessels followed by aorta and supra-aortic arteries dissection. A curve clamp was placed into the left brachiocephalic trunk (Figure 1A) and a 10 mm x 12 mm-vascular graft was sewn (tube I) using a 5-0 polypropylene suture (Figure 1B).

An arterial cannula was placed into the vascular graft close to the anastomose (Figure 1B). Details of venous cannulation depended on the associated procedures performed. Cardiopulmonary bypass was started cooling the patient at a nasopharyngeal temperature between 22°C and 25°C. A vascular clamp was placed into the ascending aorta, through coronary sinus, before retroperfusion of blood cardioplegia was started. Cooling was kept while both aortic valve surgical treatment and confection of proximal anastomosis to the tubular graft were being performed.

After proximal treatment and patient's cooling, a vascular clamp was placed into left brachiocephalic trunk (Figure 1C) allowing unilateral selective cerebral perfusion. Corporeal perfusion was interrupted, keeping only brain flow between 300 mL/min to 500 mL/min through the right carotid artery, adjusting the flow to achieve a perfusion pressure at the right radial artery between 50 mmHg and 70 mmHg. Blood was perfused toward left brachiocephalic trunk using the roller pump of heart-lung machine or a centrifuge pump, keeping the temperature between 20°C and 25°C.

Aorta was incised after the interruption of the systemic perfusion, leaving enough aortic tissue to isolate both left brachiocephalic trunk and left carotid artery (Figure 1D). The left subclavian artery was left close to the descending aorta.

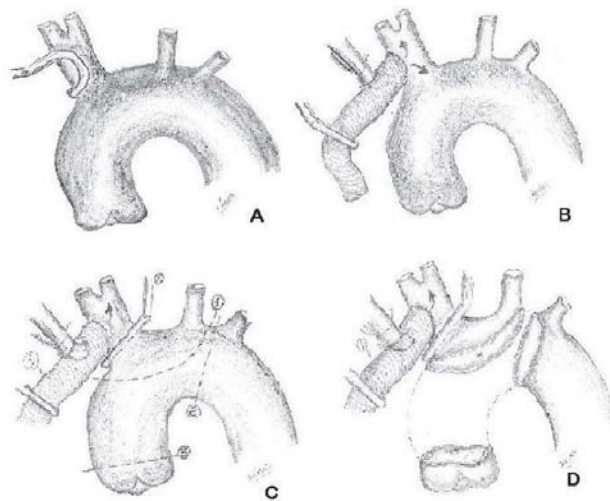


Fig. 1 – A: Positioning of the lateral “clamp” into the brachiocephalic trunk; B: 10 or 12-mm Dacron tube anastomosis (tube I) into brachiocephalic trunk. Arterial cannula implantation into tube I in order to start cardiopulmonary bypass; C: Positioning of the “clamp” into brachiocephalic trunk allowing retrograde selective cerebral perfusion during circulatory arrest; D: Resection of the aorta, leaving the left subclavian artery in the distal portion. An aortic flap is left in order to perform an isolation of both brachiocephalic trunk and left carotid artery.

The isolation of both brachiocephalic trunk and left carotid artery was achieved by aortic flap closure using a 4-00 or 5-00 polypropylene continuous suture (Figure 2A). The bilateral cerebral perfusion was kept after removal of left brachiocephalic trunk clamping. Bilateral antegrade selective cerebral perfusion was kept at a flow between 500 mL/min to 1000 mL/min at a temperature between 20°C and 25°C.

The distal portion of aorta was sectioned and prepared to receive the Dacron tubular prosthesis (Tube II). The left subclavian artery can be ligated to ease the distal anastomosis when there is a significant lesion of its own. The distal anastomosis can be performed after aortic endoprosthesis implantation, when needed. Restoration of body perfusion was performed just after the distal anastomosis completion using 4-00 polypropylene suture (Figure 2B). The left subclavian artery was kept close to the distal anastomosis. After distal anastomosis completion, an arterial cannula was inserted into the aortic prosthesis and blood was infused at a temperature of 25°C. A clamp was placed in the aortic prosthesis and body perfusion re-started (Figure 2B). Patient rewarming (3°C at each 10 minutes) was initiated during this period.

After distal and proximal aortic anastomosis was completed, a vascular prosthesis (tube I) was anastomosed to aortic tubing (tube II) with a 5-00 polypropylene continuous suture, using a lateral clamp in the aortic graft (Figure 2C).

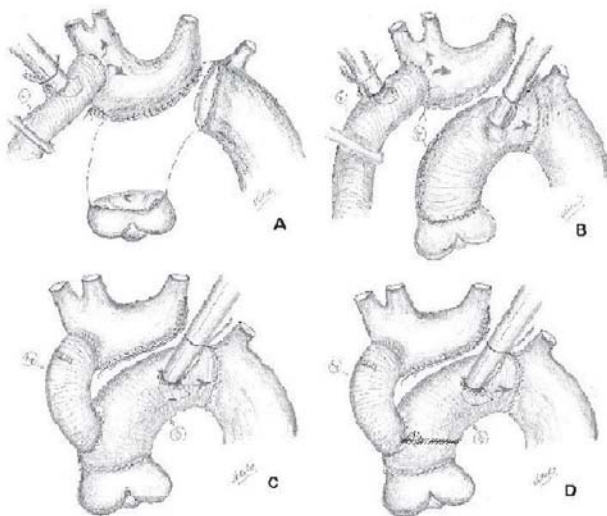


Fig. 2 – A: Flap closure with 4-00 polypropylene continuous suture. Clamp removal from the brachiocephalic trunk which allows bilateral antegrade selective cerebral perfusion; B: Tube II implantation into distal aorta and positioning of arterial cannula in order to start body rewarming; C: Tubes I and II Implantation and removal of the arterial cannula from the tube of antegrade cerebral perfusion (tube I); D: Detail of the anastomosis between tubes I and II when is used two Dacron tubes to perform valve replacement.

A cannula placed into the brachiocephalic trunk cannulation (tube I) was removed, leaving perfusion alone by the cannula placed into the aortic prosthesis (tube II). The rewarming was kept until a nasopharyngeal temperature of 36°C was reached.

Distal and proximal aortic anastomoses can be performed with separate prosthesis. In these cases, the anastomosis between tubes I and II was performed at the junction of aortic tubes (Figure 2D).

RESULTS

Of the patients who were operated on, 53.3% were male. Patients age ranged from 18 to 81 years, with a mean age of 59.86 ± 15.4 years, and median of 63 years. Four (26.6%) patients were older than 65 years; however, this factor did not have statistics association with mortality ($p > 0.05$).

Regarding baseline disease, nine (60%) patients presented acute DeBakey type II aortic dissection and one (6.7%) DeBakey Type IIIb with retrograde dissection for aortic arch and ascending aorta. Five (33.3%) patients presented ascending aortic aneurysm with aortic arch impairment. One patient with ascending aortic aneurysm presented Marfan syndrome and exhibited an aneurysmal formation due to aortic valve dysfunction.

Cardiopulmonary bypass time ranged from 120 to 240 minutes with mean of 177.6 ± 39.4 minutes and median of 168 minutes. Two (13.3%) patients underwent a period of total circulatory arrest due to technical requirements, with length of time ranging between 20 and 22 minutes. All the other patients (86.7%) underwent unilateral selective cerebral perfusion to isolation of both brachiocephalic trunk and left carotid artery; these patients did not undergo total circulatory arrest. Unilateral selective cerebral perfusion time ranged from 9 minutes to 15 minutes, with mean time of 10.9 ± 2.0 minutes and median of 10 minutes. Bilateral selective cerebral perfusion time ranged from 33 minutes to 113 minutes, with mean time of 57.2 ± 21.2 minutes and median of 50 minutes. Myocardial anoxia time ranged from 81 minutes to 190 minutes, with mean time of 135.9 ± 34.0 minutes and median of 137 minutes. The minimum temperature imposed to the patients during hypothermia ranged from 17.9°C to 25.3 °C, with mean temperature of 23.0 ± 2.9 °C and median of 27.4°C.

The main demographic and surgical data are listed in Table 1.

Regarding the surgical technique, two (13.3%) patients underwent associated procedures besides aortic valve and aorta surgery. The preservation of aortic valve with valve repair was performed in 13 (86.7%) patients. The left subclavian artery was ligated in two (13.3%) patients, and nine (60%) patients underwent distal and proximal anastomosis with separated tubes. Proximal anastomosis was performed with a 28-mm Dacron tube in nine (60%) patients; with a 30-mm Dacron tube in four (26.7%), and

with a 32-mm Dacron tube in one (6.7%). Distal anastomosis was performed with a 26-mm Dacron tube in seven (46.7%) patients, with 28-mm Dacron tube in four (26.7%), with a 30-mm Dacron tube in three (20%), and with a 32-mm Dacron tube in one (6.7%). Vascular endoprosthesis was used in the descending aorta in four (26.7%) patients.

Table 1. Description of surgical and clinical data of the surgical patients.

Clinical data	Absolute value	Percent
Gender (male)	8	53.3%
Hypertension	11	73.3%
Diabetes Mellitus	1	6.6%
CAD family history	3	20%
Smoking	2	13.3%
Dyslipidemia	2	13.3%
Reoperation	1	6.6%
Marfan Syndrome	1	6.6%
Rheumatic fever	1	6.6%
Collagenosis	1	6.6%
Stanford type A acute aortic	9	60%
Stanford type B acute aortic	1	6.6%
Aneurysm involving aortic arch	5	33.3%

Surgical Data	Mean	SD
Age (years)	59.86 years	5.4 years
CPB	177.6 min	39.4 min
Myocardial anoxia	135.9 min	34.0 min
Unilateral selective perfusion	10.9 min	2.0 min
Bilateral selective perfusion	57.2 min	21.2 min
Minimum temperature	23 °C	2.9 °C
Follow up	11.7 months	9.6 months

SD - Standard Deviation

In-hospital mortality, in this studied group, was of 20 (three patients). One patient died due to false lumen thrombosis with irrigation occlusion of abdominal vessels. The other two deaths were due to multiorgan failure by abdominal complications resulted from the dissection itself. None of the deaths were related to surgical technique complication or surgical bleeding. All three deaths occurred in the group of ten patients operated on due to acute aortic dissection with a mortality rate of 30 in this subgroup. In the group of the five patients operated on due to ascending aortic aneurysm with aortic arch impairment, there were no deaths.

When we analyzed demographic, clinical, and surgical data related with mortality, we could observe that two (28.5) deaths occurred in the group of female patients versus one (12.5) in the male group; there was no statistically significant

difference between both groups, $p > 0.05$. One (6.7) death occurred in patients over age 70 years; there was no statistical difference regarding the patients less than 70 years. All deaths occurred in the group of patients with acute aortic dissection (30); however, there was statistically significant difference if in comparison to the rest of the group, $p > 0.05$.

In-hospital mortality did not relate with cardiopulmonary bypass time neither did with myocardial anoxia time. Unilateral and bilateral selective cerebral perfusion times had no statistically significant relation with in-hospital mortality. The use of a minimum temperature below 20°C during deep hypothermia did not relate to in-hospital mortality. The ligation of the left subclavian artery, as well as distal and proximal anastomoses confection with separated or single tubes, did not show statistical relation with in-hospital mortality, $p > 0.05$. Of the four patients who underwent descending aortic vascular endoprosthesis implantation, two (50%) died; however, this group of patients did not present statistically significant in-hospital mortality difference in comparison to the group who did not receive this device.

From the neurologic standpoint, all the patients who survived had uneventful clinical outcome course with no types of immediate and late postoperative sequelae. The mean follow-up time ranged from 29 time of 11.7 ± 9.6 months and median of 10 months. All the patients who survived are still alive and under follow-up. In Figures 3 and 4, we can observe an angiotomography of 12-month follow-up postoperatively.

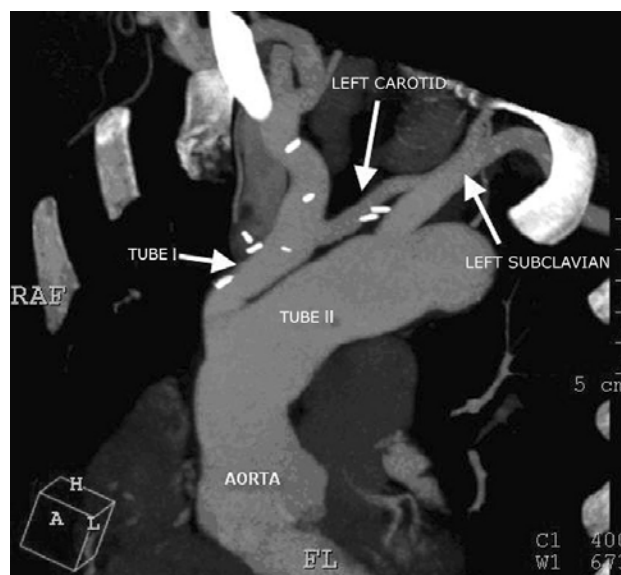

Fig. 3 – Angiotomographic study after 1 year postoperatively of a patient treated with the described technique.

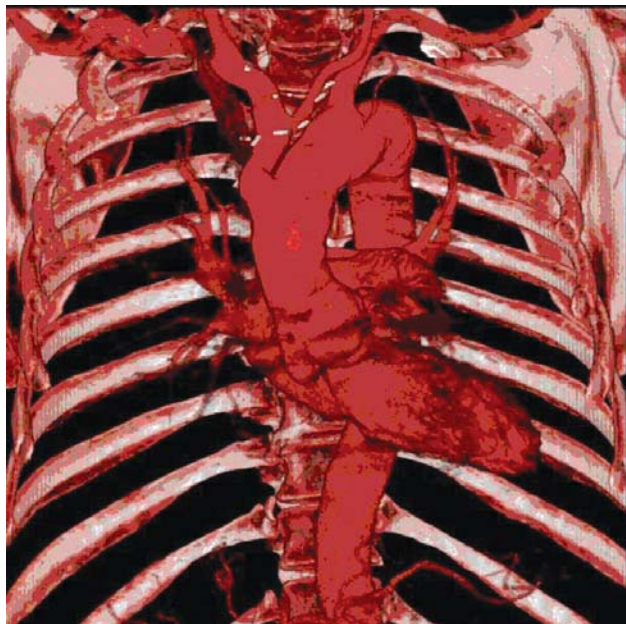


Fig. 4 – Angiotomographic study after 1 year postoperatively of a patient treated with the described technique.

DISCUSSION

Deep hypothermia with total circulatory arrest was an incontestable advance for the treatment of diseases affecting the aortic arch as reported by Svensson et al. [3]. Even thus, neurologic complications (stroke) continued to be an important determinant of morbidity [2]. One advantage of the bilateral cerebral perfusion technique just described in this study relies upon the possibility of aortic arch treatment without total circulatory arrest period.

With the introduction of retrograde cerebral perfusion by Ueda et al. [8] there has been an increase in the protection offered to the central nervous system, even thus the neurologic complications were still important; this has stimulated the need of performing cerebral perfusion antegradely. The data reported by Merkkola et al. [16] are important to understand that the cerebral hemispheres cannot provide vascular connection in up to 14% to 17% of the patients, imposing the need of bilateral selective cerebral perfusion.

Kazui et al. [18] developed a technique for bilateral perfusion using a cannula with inflatable balloons. Kazui [24] advocates that in a surgery which requires selective cerebral perfusion time superior to 30 minutes or aortic arch replacement, the bilateral perfusion method is the appropriate choice for neurologic protection. Kuriso et al. [19] described the use of bilateral cerebral perfusion through

cannulation of both axillary arteries and the insertion of a catheter into left carotid artery, thus imposing a great surgical complexity and manipulation to the procedure. Griep et al. [25] described the use of bilateral cerebral reperfusion through a Dacron tube implantation into the origin block of brachiocephalic vessels which is anastomosed posteriorly to the tube replacing the ascending aorta. In this case, the site of cannulation is the right axillary artery and the patients are under deep hypothermia between 11°C and 14°C.

Spielvogel et al. [21] described, in 2002, that the use of a trifurcated prosthesis with isolated anastomoses of brachiocephalic vessels would be more appropriated for patients with atherosclerotic aneurysms. This technique allows bilateral antegrade selective cerebral perfusion, however, perfusion is maintained via right axillary artery, mean unilateral antegrade selective cerebral perfusion time was 30 ± 6 minutes and hypothermia was kept between 11°C and 14°C. In 2007, Spielvogel et al. [22] published the results of this technique in 150 patients, with in-hospital mortality rate of 4% and permanent stroke of 4.6%.

This technique reported in this study allows the performance of bilateral antegrade selective cerebral perfusion with no need of further incisions in axillary, subclavian, or cervical region to establish cannulation site. Besides, this technique has the advantage of not involving controlled maintenance of cannulae or catheters to assure perfusion of the carotid arteries as described by Kazui et al. [18]. Minimum hypothermia temperature can be higher, once mean unilateral antegrade selective cerebral perfusion time is short (10.9 ± 2.0 minutes). Even with a small number of patients there was no mortality in aneurysmal subgroup and no permanent stroke.

The distance between brachiocephalic trunk insulation tube and the left subclavian artery allows aortic endoprosthesis implantation posteriorly without compromising tube flow of brachiocephalic trunk and left carotid artery. One patient underwent late endoprosthesis implantation which recovered the left subclavian artery, being placed at ascending aorta level without affecting cerebral blood flow.

Recently, Pacini et al. [26] reported good outcomes using hypothermia with nasopharyngeal temperatures superior to 25°C, with neurologic outcomes similar to the group of patients who underwent hypothermia below 25°C. Touati et al. [27] published surgery outcomes involving aortic arch using cardiopulmonary bypass under normothermia and without circulatory arrest in 29 patients. They reported in-hospital mortality of 6.9% and neurologic sequela of 3.4%. The technique of isolation also allows keeping the body temperature at higher levels. The patient is cooled only to 25°C, while the brain is well protected by a bilateral antegrade selective cerebral perfusion at a temperature between 20°C and 25°C. This factor allows fast rewarming with a shorter

cardiopulmonary bypass time because body temperature is kept high as reported by Carreira et al. [23]. The use of higher temperatures can reduce the harmful effects imposed by hypothermia as reported by Griep et al. [4] and contribute greatly to avoid blood dyscrasia alterations, inflammation imposed by cardiopulmonary bypass, besides reducing patient's rewarming time.

Spielvogel et al. [22] used trifurcated prosthesis with isolated anastomoses in the brachiocephalic vessels. The technique of using trifurcated prosthesis allows a good visualization of anastomoses to correct occasional bleeding in suture lines. In this group of 150 patients, 4.7 needed surgical review due to increased bleeding. In the patient group of the present study, there has not been a single bleeding case requiring hemostasis review. Probably, the disposition of both vascular prostheses allowed an easier correction of potential bleedings, especially in the posterior portion of the distal anastomosis due to an excellent visualization of the anastomoses.

In-hospital mortality outcomes from the study group are compatible with those presented by international groups. Hagan et al. [28] reported at the International Registry of Acute Aortic Dissection (IRAD), an in-hospital mortality rate of 26% for Stanford type A acute aortic dissection surgical treatment. The overall mortality for IRAD was of 27.4%, compatible with the results of the present study. There were no deaths in the group that underwent ascending aortic aneurysm and aortic arch surgery.

The absence of neurologic alteration in these studied patients demonstrates that the use of bilateral antegrade selective cerebral perfusion is effective enough in neurologic preservation during aortic arch surgery.

Even though other techniques have already been described for aortic arch repair, inclusive in national journals by Reis Filho et al. [29] and by Souza et al [30], we believe that the technique, described by Carreira et al., is original, presents a cannulation site in the same incision [23], uses hypothermia with higher temperatures, and allows cerebral perfusion without any brain flow interruption period.

CONCLUSION

The present study currently proves that the use of isolation technique of both brachiocephalic trunk and left carotid artery by the technique described by Carreira et al. is safe and presents outcomes comparable to those in the worldwide literature.

The possibility of performing hypothermia with higher levels of temperature and the promptness in suture review might have influenced the surgical outcomes achieved. The neurologic outcomes with the use of bilateral antegrade

selective cerebral perfusion and the possibility of not performing a total hypothermic arrest at any of the surgery time might have positively influenced the neurologic outcomes.

REFERENCES

1. Mujsce DJ, Towfighi J, Yager JY, Vannucci RC. Neuropathologic aspects of hypothermic circulatory arrest in newborn dogs. *Acta Neuropathol.* 1993;85(2):190-8.
2. Ergin MA, Galla JD, Lansman L, Quintana C, Bodian C, Griep RB. Hypothermic circulatory arrest in operations on the thoracic aorta. Determinants of operative mortality and neurologic outcome. *J Thorac Cardiovasc Surg.* 1994;107(3):788-99.
3. Svensson LG, Crawford ES, Hess KR, Coselli JS, Raskin S, Shenag SA, et al. Deep hypothermia with circulatory arrest. Determinants of stroke and early mortality in 656 patients. *J Thorac Cardiovasc Surg.* 1993;106(1):19-31.
4. Griep RB, Ergin MA, Lansman SL, Galla JD, Pogo G. The physiology of hypothermic circulatory arrest. *Semin Thorac Cardiovasc Surg.* 1991;3(3):188-93.
5. Kazui T, Kimura N, Yamada O, Komatsu S. Surgical outcome of aortic arch aneurysms using selective cerebral perfusion. *Ann Thorac Surg.* 1994;57(4):904-11.
6. Kazui T, Kimura N, Komatsu S. Surgical treatment of aortic arch aneurysms using selective cerebral perfusion. Experience with 100 patients. *Eur J Cardiothorac Surg.* 1995;9(9):491-5.
7. Dossche KM, Schepens MA, Morshuis WJ, Muysoms FE, Langemeijer JJ, Vermeulen FE. Antegrade selective cerebral perfusion in operations on the proximal thoracic aorta. *Ann Thorac Surg.* 1999;67(6):1904-10.
8. Ueda Y, Miki S, Kusuhara K, Okita Y, Tahata T, Yamanaka K. Surgical treatment of aneurysm or dissection involving the ascending aorta and aortic arch utilizing circulatory arrest and retrograde cerebral perfusion. *J Cardiovasc Surg.* 1990;31(5):553-8.
9. Usui A, Abe T, Murase M. Early clinical results of retrograde cerebral perfusion for aortic arch operations in Japan. *Ann Thorac Surg.* 1996;62(1):94-104.

10. Ueda Y, Okita Y, Aomi S, Koyanagi H, Takamoto S. Retrograde cerebral perfusion for aortic arch surgery: analysis of risk factors. *Ann Thorac Surg.* 1999;67(6):1879-82.
11. Dias RR, Silva IA, Fiorelli AI, Stolf NAG. Proteção cerebral: sítios de canulação arterial e vias de perfusão do cérebro. *Rev Bras Cir Cardiovasc.* 2007;22(2):235-40.
12. Coselli JS, LeMaire SA. Experience with retrograde cerebral perfusion during proximal aortic surgery in 290 patients. *J Card Surg.* 1997;12(2 Suppl):322-5.
13. Safi HJ, Letsou GV, Iliopoulos DC, Subramaniam MH, Miller CC 3rd, Hassoun H, et al. Impact of retrograde cerebral perfusion on ascending aortic and arch aneurysm repair. *Ann Thorac Surg.* 1997;63(6):1601-7.
14. Okita Y, Minatoya K, Tagusari O, Ando M, Nagatsuka K, Kitamura S. Prospective comparative study of brain protection in total aortic arch replacement: deep hypothermic circulatory arrest with retrograde cerebral perfusion or selective antegrade cerebral perfusion. *Ann Thorac Surg.* 2001;72(1):72-9.
15. Ohmi M, Tabayashi K, Hata M, Yokoyama H, Sadahiro M, Saito H. Brain damage after aortic arch repair using selective cerebral perfusion. *Ann Thorac Surg.* 1998;66(4):1250-3.
16. Merkkola P, Tulla H, Ronkainen A, Soppi V, Oksala A, Koivisto T, et al. Incomplete circle of Willis and right axillary artery perfusion. *Ann Thorac Surg.* 2006;82(1):74-9.
17. Bachet J, Guilmet D, Goudot B, Termignon JL, Teodori G, Dreyfus G, et al. Cold cerebroproplegia. A new technique of cerebral protection during operations on the transverse aortic arch. *J Thorac Cardiovasc Surg.* 1991;102(1):85-94.
18. Kazui T, Inoue N, Yamada O, Komatsu S. Selective cerebral perfusion during operation for aneurysms of the aortic arch: a reassessment. *Ann Thorac Surg.* 1992;53(1):109-14.
19. Kurisu K, Ochiai Y, Hisahara M, Tanaka K, Onzuka T, Tominaga R. Bilateral axillary arterial perfusion in surgery on thoracic aorta. *Asian Cardiovasc Thorac Ann.* 2006;14(2):145-9.
20. Minatoya K, Ogino H, Matsuda H, Sasaki H, Yagihara T, Kitamura S. Surgical management of distal arch aneurysm: another approach with improved results. *Ann Thorac Surg.* 2006;81(4):1353-7.
21. Spielvogel D, Strauch JT, Minanov OP, Lansman SL, Griep RB. Aortic arch replacement using a trifurcated graft and selective cerebral antegrade perfusion. *Ann Thorac Surg.* 2002;74(5):S1810-4.
22. Spielvogel D, Etz CD, Silovitz D, Lansman SL, Griep RB. Aortic arch replacement with a trifurcated graft. *Ann Thorac Surg.* 2007;83(2):S791-5.
23. Carreira VJ, de Oliveira DM, Pinheiro AP, Magalhães JFD, Pinheiro ITF, Albuquerque DC, et al. Técnica de Carreira: uma nova técnica para cirurgia do arco aórtico com perfusão cerebral seletiva anterógrada e bilateral através do isolamento do tronco braquiocéfálico e carótida esquerda. *Revista SOCERJ.* 2006;19(4):469-73.
24. Kazui T. Which is more appropriate as a cerebral protection method: unilateral or bilateral perfusion? *Eur J Cardiothorac Surg.* 2006;29(6):1039-40.
25. Griep RB, Ergin MA. Aneurysms of the aortic arch. In: Edmunds Jr LH, ed. *Cardiac surgery in the adult.* New York:McGraw-Hill;1997. p.1209.
26. Pacini D, Leone A, Di Marco L, Marsilli D, Sobaih F, Turci S, et al. Antegrade selective cerebral perfusion in thoracic aorta surgery: safety of moderate hypothermia. *Eur J Cardiothorac Surg.* 2007;31(4):618-22.
27. Touati GD, Marticho P, Farag M, Carmi D, Szymanski C, Barry M, et al. Totally normothermic aortic arch replacement without circulatory arrest. *Eur J Cardiothorac Surg.* 2007;32(2):263-8.
28. Hagan PG, Nienaber CA, Isselbacher EM, Bruckman D, Karavite DJ, Russman PL, et al. The international Registry of Acute Aortic Dissection (IRAD). New insights into an old disease. *JAMA.* 2000;283(7):897-903.
29. Reis Filho FAR, Lima LCM, Silveira EL, Bernardes RC. Substituição do arco aórtico sem parada circulatória total: técnicas, táticas e resultados. *Rev Bras Cir Cardiovasc.* 2001;16(3):226-35.
30. Souza JM, Rojas SO, Berlinck MF, Mazzieri R, Oliveira PAF, Martins JRM, et al. Circulação extracorpórea pela artéria carótida comum direita na correção de doenças da aorta ascendente, arco aórtico e aorta descendente. *Rev Bras Cir Cardiovasc.* 2003;18(2):137-41.