

# Left thoracotomy for reoperations in myocardium revascularization

## *Toracotomia esquerda para reoperação de revascularização miocárdica*

Carlos Sérgio Luna Gomes DUARTE<sup>1</sup>, Fernando Ribeiro de MORAES NETO<sup>2</sup>, Carlos Roberto Ribeiro de MORAES<sup>3</sup>

RBCCV 44205-910

### *Abstract*

**Objective:** To describe patient selection criteria, surgical technique and early outcomes in patients undergoing reoperative coronary artery bypass surgery (RECABG) through a left thoracotomy without cardiopulmonary bypass (CPB).

**Methods:** Eight patients with patent grafts to the anterior interventricular branch of left coronary artery (four of which had also patent grafts to the right coronary artery) requiring revascularization of the circumflex coronary system had

redo-CABG without CPB through a left posterolateral thoracotomy.

**Results:** There was no in-hospital mortality or serious postoperative complications. All patients are angina-free.

**Conclusions:** An off-pump redo-CABG through a left posterolateral thoracotomy may reduce risks attributable to re sternotomy in patients who met the selection criteria.

**Descriptors:** Myocardial revascularization. Reoperation. Coronary artery bypass, methods. Thoracotomy.

1. Residency on Cardiovascular Surgery; Cardiovascular Surgeon.
2. MD - Cardiovascular Surgery; Cardiovascular Surgeon.
3. Professor of Thoracic Surgery - Universidade Federal de Pernambuco; Head Surgeon.

This study was performed at the Heart Institute of Pernambuco (Real Hospital Português de Beneficência em Pernambuco), Recife, PE, Brazil.

Correspondence address:

Instituto do Coração de Pernambuco (Real Hospital Português de Beneficência em Pernambuco). Carlos Roberto Ribeiro de Moraes. Av. Portugal, 163 – Recife, PE – CEP 52010-010  
Fone: (81) 3221 0382.  
E-mail address: cmoraes@uol.com.br

Article received in February, 14<sup>th</sup>, 2007

Article accepted in July 4<sup>th</sup>, 2007

### Resumo

**Objetivo:** Descrever a seleção de pacientes, a técnica cirúrgica e os resultados imediatos de reoperação de revascularização miocárdica sem circulação extracorpórea através de toracotomia pótero-lateral esquerda.

**Método:** Oito pacientes com pontes púrvias para a artéria interventricular anterior (quatro dos quais também tinham pontes púrvias para a artéria coronária direita) foram submetidos à reoperação sem circulação extracorpórea através de toracotomia pótero-lateral esquerda.

**Resultados:** Não houve mortalidade hospitalar ou complicação pós-operatória significativa. Todos os pacientes estão assintomáticos.

**Conclusões:** Em pacientes selecionados, reoperação de revascularização miocárdica sem circulação extracorpórea e através de toracotomia esquerda pode reduzir os riscos da resternotomia.

**Descritores:** Revascularização miocárdica. Reoperação. Ponte de artéria coronária, métodos. Toracotomia.

## INTRODUCTION

Although the outcomes of reoperative coronary artery bypass grafting have been improved along the years [1], some clinical situations, such as the internal thoracic artery grafts, carry a higher risk during resternotomy. In 1982, Cheung et al; [2] and Faro et al. [3] independently described the experience in performing left thoracotomy for circumflex coronary artery revascularization in patients who had undergone previous cardiac surgery. The use of left thoracotomy for myocardial revascularization, besides to have been proven as a simple technique, has been sporadically reported [4-15]. Our first experience was with a patient who required coronary artery bypass grafting concomitant with an aortic coarctation [16]. Since then, other 8 patients have undergone surgery.

The aim of the present study is to attract attention upon to this technical option of coronary surgery.

## METHODS

Between February 2003 and April 2005, 8 patients underwent reoperative off-pump coronary artery bypass grafting (CABG), at the Heart Institute of Pernambuco, Recife, PE, Brazil, through left thoracotomy. Of the 8 studied patients, 7 were male and 1 was female. The ages ranged from 60 to 85 years (mean age of 69.6 years). The main data related to the previous surgery (date and CABG performed) are listed in Table 1.

The time between the first and the second surgery varied from 4 to 23 years (mean of 12 years). All patients had angina pectoris. Basically, the choice of the technique was due to the presence of the patent grafts, especially the

internal thoracic artery grafting to the anterior interventricular branch of left coronary artery, and the need to revascularize the circumflex branch of left coronary artery. Besides the revascularization of the circumflex branch of left coronary artery, the anterior interventricular branch of left coronary artery (case 3) and the diagonal branch of left coronary artery (case 4).

After general anesthesia, a tracheal intubation with a Carlen double-lumen, flexible endobronchial tube, which allowed the left lung collapse after the thoracotomy, was performed. With the patient still in supine position, a saphenous vein was obtained from the right leg. The patient was then moved to a lateral recumbent position and a left posterolateral thoracotomy through the 5<sup>th</sup> intercostal space was performed.

Once the thorax was opened, the ventilation to the left lung was suspended and the pericardium was incised longitudinally anterior to the phrenic nerve (Figure 1). Heparin was administered in a dose of 4.0 mg/kg body weight. When the artery to be revascularized was identified, it was sutured with continuous 4-0 polypropylene suture to interrupt the blood flow (Figure 2). A suction stabilizer (Octopus II, Medtronic, Inc.; Minneapolis, Minn) was used to stabilize the artery in order to construct the anastomosis with the use of the saphenous vein (Figure 3). The anastomosis was performed with a continuous 7-0 polypropylene suture (Figure 4). The proximal saphenous vein grafting anastomosis was made to the descending aorta in 7 cases (Figure 5), and to the left subclavian artery in 1 case. Partial occlusion clamping and continuous 6-0 polypropylene suture was used. Once the saphenous vein grafting was concluded, the left lung was reexpanded, the heparin was reverted with an equal dose of protamine sulfate, and the thorax was drained and closed by layers.

Table 1. Summary of Clinical Data

Case	Age	Gender	Previous operation and date	Cine pós-operatória	Operation and date
1	60	M	1994 ITA ADA SVGB 1ª Mg 3ª Mg Diagonal	2003 patent ITA SVGB occluded CX injury	12/02/03 SVGB Mg
2	66	M	1999 ITA ADA SVGB 1ª Mg	2003 ITA patent Patent SVGB 2ª Mg injury	02/04/03 SVGB Mg
3	85	M	1980 ITA ADA SVGB CD 1ª Mg	2003 Important injury in anastomosis ITA-ADA SVGB patent RCA SVGB Mg occluded	14/05/03 SVGB DA PS Mg
4	61	M	1994 ATI DA PS CD	2003 ITA patent ADA SVGB patent RCACX and Diagonal injury	02/06/03 SVGB Diagonal SVGB Mg
5	71	M	1980 ITA ADA SVGB Diagonal SVGB Mg	2004 ITA patent ADA SVGB patent Diag SVGB Mg occluded	08/01/04 SVGB Mg
6	72	F	1987 SVGB DA SVGB RCA	2004 TCA with Stent in SVGB ADA SVGB RCA occluded Trunk injury	11/02/04 SVGB Mg
7	75	M	1993 ITA ADA SVGB RCA	2004 ITA ADA patent SVGB patent RCA CX injury	08/11/04 SVGB Mg
8	67	M	1994 ITA ADA SVGB Diagonal Mg RCA	2005 ITA ADA patent SVGB patent RCA SVGB Mg and Diagonal occluded CX injury	20/04/05 SVGB Mg

ITA – Internal Thoracic Artery; ADA - Anterior Descending Artery; SVGB - Saphenous vein Graft Bypass; Mg - Marginal Branch of CX; CX – Circumflex Artery; RCA – Right coronary artery; TCA- Transluminal coronary angioplasty; ATI - Artéria Torácica Interna; DA - Artéria Descendente Anterior; PS - Ponte de Safena; Mg - Marginal da CX; CX - Artéria Circunflexa; CD - Artéria Coronária Direita; ATC - Angioplastia Transluminal Coronariana

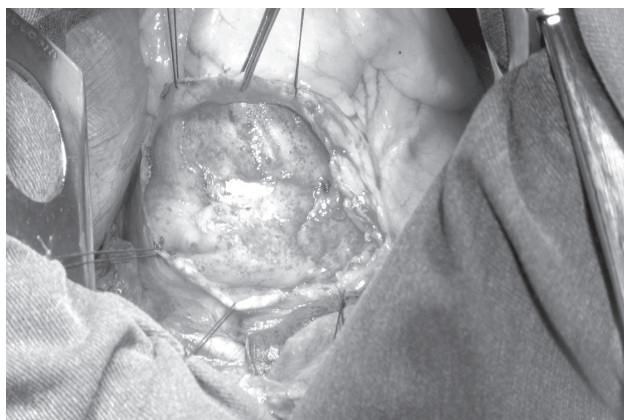


Fig. 1 – Aspect of the exposure of the posterolateral surface of left ventricle through left thoracotomy

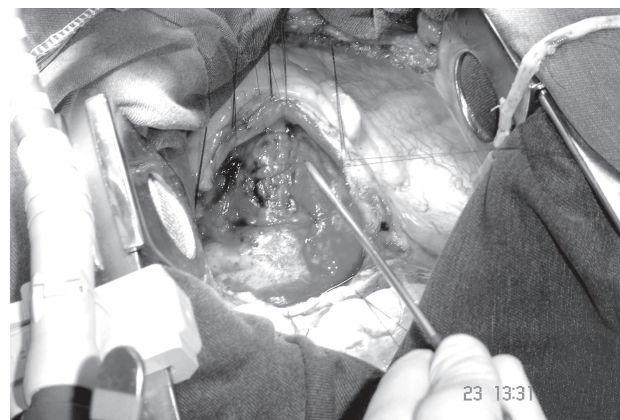


Fig. 2 – Marginal branch of the circumflex artery sutured with 4-0 polypropylene suture

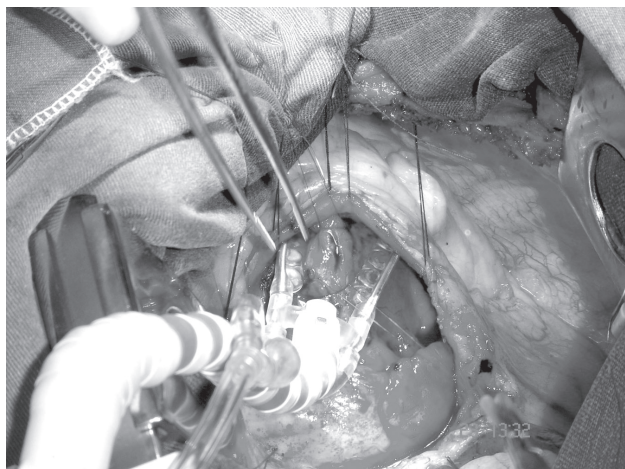


Fig. 3 – Stabilization of the artery to perform the anastomosis with the Octopus stabilizer

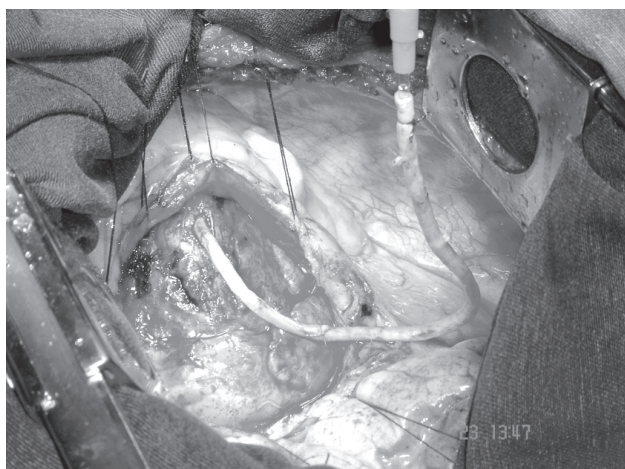


Fig. 4 – Distal anastomosis of the occluded saphenous vein graft bypass

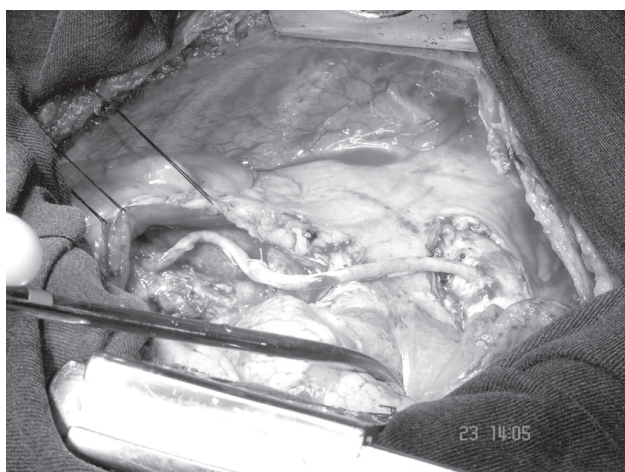


Fig. 5 – Final aspect of the saphenous vein graft bypass. It can be observed the anastomoses in the circumflex artery and in the descending aorta

## RESULTS

We have not observed any technical difficulties in identifying the artery to be revascularized. Overall, 10 saphenous vein graftings were performed as follows: 8 to the left marginal artery of circumflex branch; 1 to the anterior interventricular branch; and 1 to the diagonal branch of anterior interventricular branch of left coronary artery. Also, due to the pulmonary collapse, there were no difficulties in performing the anastomosis to the descending aorta. The surgery was uneventful. No hemodynamic instability or electrocardiographic changes were seen in any patient.

There were no deaths; no need to reoperate for bleeding; and no pulmonary or neurologic complications. Only one patient needed to make a new drainage of the left hemithorax due to postoperative pleural effusion.

All patients acknowledged angina relief and are now asymptomatic from the cardiovascular standpoint.

## DISCUSSION

Judging by the existing number of publications, it seems that the CABG technique through left thoracotomy has not been used in spite of its undeniable advantage in some cases, once this procedure can reduce the risks of rethoracotomy and heart dissection, such as hemorrhage, ITA grafting injury, and embolization by manipulating the saphenous vein bypass grafts.

Among the occasional candidates to this technical option, patients with ITA or saphenous vein patent grafts to the anterior interventricular branch and right coronary artery, and those who require revascularization of the circumflex coronary system are included.

Other indications would be as follows: calcified ascending aorta, sternum osteomyelitis or mediastinitis in the first operation, mediastinal irradiation, requirement of concomitant left lung surgery and previous mitral valve replacement, what makes risky to rotate the heart to approach the posterior arteries [3, 4, 6].

In the Cleveland Clinic experience [14], 2.5% of the patients eligible to redo-CABG were included in these indications. Our cases fell into the classical indication: a) all the 8 patients has patent grafts to the anterior interventricular branch; although one of them presented anastomotic stenosis, and another one had injury in the diagonal branch of the anterior interventricular branch; b) four patients also presented patent grafts to the right coronary artery; c) all of them has stenotic injury in the circumflex branch requiring revascularization.

Also, it is observed in the review of the literature that the operative technique has varied a lot. The majority of the groups have been using some type of extracorporeal circulation with the femoro-femoral bypass being the most

used [2-10]. Some groups have been using hypothermia and ventricular fibrillation to make the anastomoses [2, 4]. The growing familiarity with the off-pump coronary artery bypass grafting technique has showed that there is no need for perfusional support [12, 14, 15]. Our early experience using the technique standardized by Azoury et al. [14] and Mack et al. [15] showed that this approach is safe and effective and low operative risks. This approach was associated with no mortality in 21 and 32 patients, respectively.

We emphasized the need to use the double-lumen endotracheal tube, which facilitates the whole operation, especially the access to the descending aorta. There is a consensus that the most difficult part of the operation is to connect the vein to the descending artery [14, 15].

In summary, the advantages in avoiding the re-sternotomy and the CABG make the redo-CABG through a left posterolateral thoracotomy, especially to the circumflex branch, and in selected patients, an excellent technical option.

#### REFERENCES

1. Loop FD, Lytle BW, Cosgrove DM, Woods EL, Stewart RW, Golding LA, et al. Reoperation for coronary atherosclerosis. Changing practice in 2509 consecutive patients. *Ann Surg.* 1990;212(3):378-85.
2. Cheung D, Flemma RJ, Mullen DC, Lepley D Jr. An alternative approach to isolated circumflex coronary bypass reoperations. *Ann Thorac Surg.* 1981;33(3):302-3.
3. Faro RS, Javid H, Najafi H, Serry C. Left thoracotomy for reoperation for coronary revascularization. *J Thorac Cardiovasc Surg.* 1982;84(3):453-5.
4. Ungerleider RM, Mills NL, Wechsler AS. Left thoracotomy for reoperative coronary artery bypass procedures. *Ann Thorac Surg.* 1985;40(1):11-5.
5. Knight JL, Cohn LH. Left thoracotomy and femoro-femoral bypass for reoperative revascularization of the posterior coronary circulation. *J Card Surg.* 1987;2(3):343-9.
6. Burlingame MW, Bonchek LI, Vazales BE. Left thoracotomy for reoperative coronary bypass. *J Thorac Cardiovasc Surg.* 1988;95(3):508-10.
7. Militano TC, Madoff IM, Moon RH. Left thoracotomy for secondary revascularization of the circumflex coronary artery with late follow-up. *Tex Heart Inst J.* 1989;16(4):305-6.
8. Gandjbakhch I, Acar C, Cabrol C. Left thoracotomy approach for coronary artery bypass grafting in patients with pericardial adhesions. *Ann Thorac Surg.* 1989;48(6):871-3.
9. Grosner G, Lajos TZ, Schimert G, Bergsland J. Left thoracotomy reoperation for coronary artery disease. *J Card Surg.* 1990;5(4):304-8.
10. Suma H, Kigawa I, Horii T, Tanaka J, Fukuda S, Wanibuchi Y. Coronary artery reoperation through the left thoracotomy with hypothermic circulatory arrest. *Ann Thorac Surg.* 1995;60(4):1063-6.
11. Pires MTB, Rego AT, Vigil RGV, Alves SL, Carvalho HF, Orlando RF, et al. Toracotomia esquerda como via de acesso para reoperações de revascularização do miocárdio. *Rev Med Minas Gerais.* 1993;3(2):100-2.
12. Baumgartner FJ, Gheissari A, Panagiotides GP, Capouya ER, Declusin RJ, Yokoyama T. Off-pump obtuse marginal grafting with local stabilization: thoracotomy approach in reoperations. *Ann Thorac Surg.* 1999;68(3):946-8.
13. Ricci M, Karamanoukian HL, D'Ancona G, Salerno TA, Bergsland J. Reoperative "off-pump" circumflex revascularization via left thoracotomy: how to prevent graft kinking. *Ann Thorac Surg.* 2000;70(1):309-10.
14. Azoury FM, Gillinov AM, Lytle BW, Smedira NG, Sabik JF. Off-pump reoperative coronary artery bypass grafting by thoracotomy: patient selection and operative technique. *Ann Thorac Surg.* 2001;71(6):1959-63.
15. Mack MJ, Dewey TM, Magee MJ. Facilitated anastomosis for reoperative circumflex coronary revascularization on the beating heart through a left thoracotomy. *J Thorac Cardiovasc Surg.* 2002;123(4):816-7.
16. Moraes F, Lamprea D, Wanderley J, Moraes CR. Correction of coarctation of the aorta with simultaneous off-pump myocardial revascularization. *Tex Heart Inst J.* 2003;30(4):332-4.