

Minimally invasive thoracotomy (muscle-sparing thoracotomy) for occlusion of ligamentum arteriosum (ductus arteriosus) in preterm infants

Toracotomia minimamente invasiva (miopreservadora) para ligadura do canal arterial em prematuros

Andrey José de Oliveira MONTEIRO¹, Leonardo Secchin CANALE², Rosie Vivian ROSA³, Alexandre Siciliano COLAFRANCESCHI⁴, Divino F. PINTO⁴, Marcia BALDANZA⁵, Rosa Célia BARBOSA⁶, Milton Ary MEIER⁷

RBCCV 44205-902

Abstract

Objectives: To analyze the feasibility, the safety, and the primary outcomes of a minimally invasive thoracotomy for the occlusion of ductus arteriosus (ligamentum arteriosum) in preterm infants.

Methods: Between October 1991 and June 2003, 273 preterm infants and very low birth weight preterm infants were submitted to a surgical occlusion of the ductus arteriosus (ligamentum arteriosum) through muscle-sparing thoracotomy under general anesthesia in the neonatal ICU. Pre-operative demographic data, mortality outcomes, and adverse events were retrospectively analyzed through medical records research.

Results: There were no deaths related to surgery, and 234 (86%) patients were discharged from hospital. Thirty-nine deaths have occurred between the 1st and the 51st days. The cause of death was sepsis (14 patients); intracranial

bleeding (11 patients); and necrotizing enterocolitis (nine patients). All causes of death were related to prematurity. In five patients the cause of death was not established or could not be found in the medical records. The most frequent adverse events related to the surgery were: pneumothorax: 3.3% (nine patients), bleeding: 1.4% (four patients).

Conclusions: The minimally invasive thoracotomy technique for the occlusion of the ductus arteriosus (ligamentum arteriosum) when performed in preterm infants and very low birth weight infants is feasible, safe, efficient, related to low morbidity, and not dependent of hospital resources.

Descriptors: Ductus arteriosus, Patent, surgery. Ductus arteriosus. Infant. Infant, Very Low Birth Weight. Thoracotomy.

1. Cardiovascular Surgeon.
2. General Surgeon - Hospital Universitário Clementino Fraga Filho.
3. Physician, Anesthesiologist - Hospital Pró-Cardíaco.
4. Cardiovascular Surgeon - Hospital Pró-Cardíaco.
5. Physician; Head of the Hospital Pró-Cardíaco Anesthesia Department.
6. Physician; Head of Hospital Pró-Cardíaco Pediatric Cardiology Service
7. PhD; Head of Hospital Pró-Cardíaco Pediatric Cardiology Surgery Service

Work performed at Hospital Pró-Cardíaco, Rio de Janeiro, RJ, Brazil.

Correspondence address:

Andrey José de Oliveira Monteiro
Av. Sernanbetiba 4.600 Bloco 5 Apt: 903 - Rio de Janeiro, RJ, Brasil
- CEP: 22630-011.
E-mail: amonteiro@cardiosuporte.com.br

Article received in February 4th, 2007

Article accepted in August 2nd, 2007

Resumo

Objetivo: Avaliar a aplicabilidade, segurança e resultados iniciais da toracotomia minimamente invasiva para ligadura do canal arterial em prematuros.

Método: Entre outubro de 1991 e julho de 2003, 273 prematuros e prematuros extremos foram submetidos à ligadura cirúrgica do canal arterial por toracotomia miopreservadora, com anestesia geral, em UTI neonatal. Os dados demográficos pré-operatórios e os desfechos de mortalidade e eventos adversos foram, retrospectivamente, avaliados por meio de consulta aos prontuários.

Resultados: Não houve óbito relacionado com o ato operatório e 234 (86%) pacientes tiveram alta hospitalar. Os 39 óbitos ocorreram entre o 1º e o 51º dias e foram atribuídos à sepsis (14 pacientes), hemorragia intracraniana

(11 pacientes), enterocolite necrotizante (nove pacientes), todas causas inerentes à prematuridade. Em cinco pacientes, a causa não foi adequadamente estabelecida. As complicações mais frequentes relacionadas ao procedimento foram: pneumotórax 3,3% (nove pacientes) e hemorragia 1,4% (quatro pacientes).

Conclusões: A técnica de toracotomia minimamente invasiva para a ligadura do canal arterial quando realizada em prematuros e prematuros extremos é aplicável, segura, eficaz, relacionada à baixa morbidade e não depende da estrutura hospitalar local.

Descritores: Persistência do conduto arterioso, cirurgia. Conduto arterioso. Prematuro. Recém-nascido de muito baixo peso. Toracotomia.

INTRODUCTION

Patent ductus arteriosus with systemic pulmonary “shunt” in preterm infants and very low birth weight preterm infants with respiratory distress syndrome (RDS) frequently causes congestive heart failure and it is associated with bronchopulmonary dysplasia, necrotizing enterocolitis, intracranial hemorrhage, and high mortality rate [1-4]. At present, this congenital malformation is the most common neonatal period anomaly [5]. The delay in the closure of the ductus is inversely proportional to the gestational age and its incidence varies up to 32 weeks of pregnancy in 20% of the premature infants and less than 28 weeks of pregnancy in 60% of the premature infants [4]. The interruption of this “shunt” improves the pulmonary compliance, reduces the duration of mechanical ventilation, and improves the nutritional condition [6,7]. This interruption can be performed by surgery ligation, or pharmacologically, by administering an inhibitor of prostaglandin, indomethacin, which is the most classically used.

The introduction of indomethacin to close pharmacologically the patent ductus arteriosus in the premature infant has raised a controversy which is not definitely solved yet. The advantages of the surgical ligation are low morbidity and mortality, besides the fast and definitive closure of the ductus. The well-known disadvantages are the surgery inherent risks and the potential harmful effects of the long-term thoracotomy [1,8]. The great advantage of the indomethacin to many authors [9] would be to interrupt the ductus arteriosus, avoiding surgery, because this drug can produce renal failure, necrotizing enterocolitis, bowel perforation, and coagulopathies, besides promoting the temporary closure of the ductus with further reopening or failure in 25-33% of

the cases [5,10].

At the moment, in the majority of the groups in Brazil, the surgical treatment to interrupt the ductus arteriosus is reserved for patients in whom this fails or in whom there are contra-indications to medical treatment. Many access pathways are proposed to approach the posterior mediastinum, where the PDA lies, and many techniques have been described to perform its closure.

OBJECTIVES

To evaluate the applicability, the safety, and the immediate outcomes of a minimally invasive thoracotomy as an access pathway for the surgery closure of patent ductus arteriosus in preterm infants.

METHODS

The medical records of all the patients who have undergone surgical closure of the patent ductus arteriosus at different neonatal units in Rio de Janeiro was performed through a descriptive, retrospective study. All pre and postoperative data were collected. The cause of death of five patients (13%) was not registered in the medical record.

Between October 1991 and June 2003, 273 preterm infants have undergone surgical ligation of the patent ductus arteriosus through muscle-sparing thoracotomy under general anesthesia in the neonatal ICU.

The indications for surgery were therapeutic failure after the use of inhibitors of prostaglandin, contraindications to the use of these drugs (sepsis, hyperbilirubinemia, coagulation disorder, renal failure).

Surgery was performed in less than 24 hours following the indication. The aforementioned technique was used in all the cases. The majority of the patients were male (124

patients) and the mean gestational age was 29.30 ± 2.84 (interquartile range [IQR] 23, 33) weeks, the mean weight was 1045 ± 538 (IQR 490, 2450) g, and the mean age was 8.55 ± 7.17 (IQR 1, 34) days. A hundred and seven patients (39.19%) weighed less than 1000 g (very low birth weight preterm infants). All the patients had respiratory distress syndrome and 212 patients (78%) were intubated and receiving mechanical ventilation.

All the surgical procedures of ligation of the patent ductus in this series were performed at the neonatal ICU, in warm bed, under general anesthesia and with endotracheal intubation.

The anesthetic technique used was the total intravenous anesthesia with phentanyl (5-10 $\mu\text{g}/\text{kg}$) and atracurium (0.3 to 0.5 mg/kg). During anesthesia, the mechanical ventilation was performed using Baraka and Jackson-Rees' systems. The duration of surgery has never surpassed 30 minutes (mean of 18 minutes).

The patients were placed on right lateral recumbent position over a pad, with the left arm over the head (Figure 1). A small incision is made parallel to the posterior and inferior borders of scapula. The thoracotomy should be small considering the size of the patient, and should preserve the serratus anterior and *latissimus dorsi* muscles. Beginning in the auscultatory triangle, these two muscles are partially isolated and pulled away without cutting them (Figures 2 and 3).

Afterwards, the intercostal muscles are divulsed with two Halsted forceps. A small Weitlaner autostatic retractor is placed between the 3rd and 4th ribs and smoothly opened, trying to withdraw the ribs without opening the pleura. Another retractor is used contralateral withdrawing the skin only. With the aid of a 10-mm width, small, malleable retractor, the pleura and the lung are progressively displaced anteriorly.

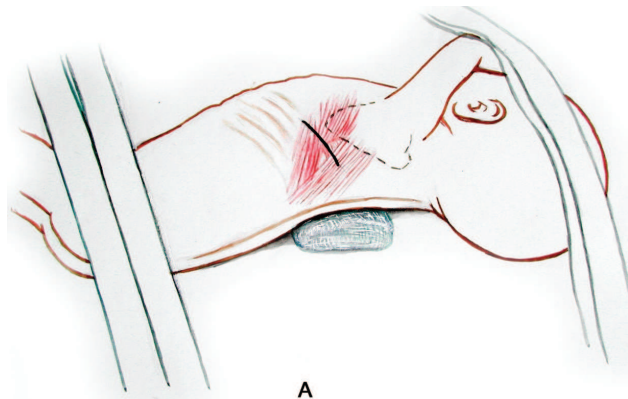


Fig. 1 – Neonate's position during the procedure

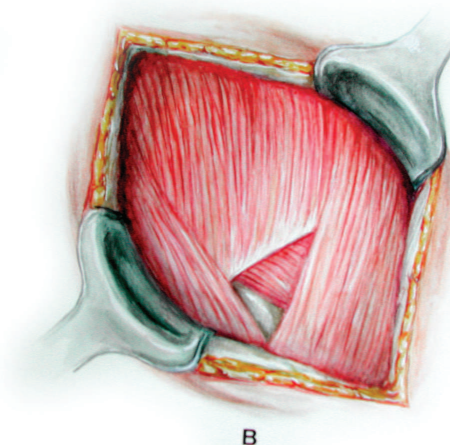


Fig. 2 – Auscultatory triangle exposure

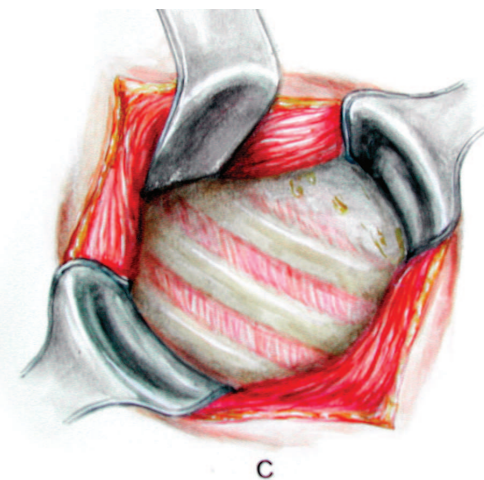


Fig. 3 – Auscultatory triangle – the muscles are drawn and the ribs are exposed

The parietal pleura comes off easily from the wall without rupturing. The descending aorta is located and the retractor move forward to the region of the ductus. The vagus and the recurrent laryngeal nerves are identified and withdraw medially. With a dissecting forceps (tweezers) and a Halsted forceps, the duct is released from the underlying adhesions and 2 metal clips LT 200 are placed interrupting the ductus (Figure 4).

The pleura is drained only in the presence of a previous pneumothorax, injury to the pulmonary parenchyma with evident fistula, or in patients who present operative bleeding larger than the expected.

The ribs are brought together with only one 3-0 Vicryl® stitch. At this moment, a continuous positive pressure is kept to expand the lungs and to avoid residual

pneumothorax. The muscles are brought together with three or four 5-0 Vycril® stitches and the skin with an intradermal 5-0 Monocryl suture.

In the majority of the cases, just after the conclusion of the surgical procedure, the neonate already presented spontaneous movement.

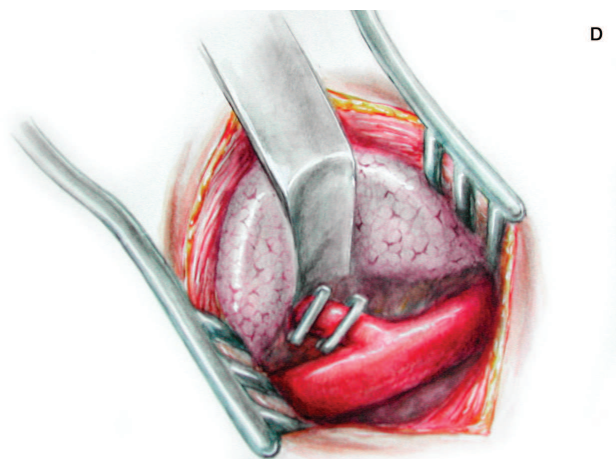


Fig. 4 – Exposure of the double-clipped patent ductus arteriosus. The lung withdrawn anteriorly

RESULTS

No neonate died as a direct result of operative procedure (significant bleeding or severe injury of important structures) and 234 (86%) patients were discharged from the hospital. The 29 deaths occurred between days 1 and 51 and they were ascribed to sepsis (14 patients), intracranial hemorrhage (11 patients), necrotizing enterocolitis (9 patients). In five patients, the cause of death was not properly established. The most frequent complications were as follows: pneumothorax 3.3% (9 patients) and hemorrhage 1.4% (4 patients). There were no cases of surgical wound infection.

DISCUSSION

In this patient population, the surgery is performed at the neonatal ICU because the transference to the hospital surgical department is almost always followed by clinic deterioration, besides the inherent risks associated with the transportation itself, such as the loss of venous lines and inadequate mechanical ventilation [11, 12]. Because it

is a simple procedure, the structure of the hospital surgical department is avoided; this is another important reason to be taken into consideration. Not all the ICUs are located near the hospital surgical department. The transport is often time-consuming, being necessary to use elevators, what makes the patient more vulnerable to inadequate handling. The planning of personnel and material availability to perform the surgery at the ICU setting is essential. All personnel directly involved with the procedure should use surgical mask and bouffant cap. When needed, the drapes should be placed in a way to provide the anesthesiologist an easy access to venous pathways and endotracheal tube [12]. Often, the option is to increase FiO_2 through mechanical ventilation to deal better with the left lung compression during the surgery. When the procedure is completed, one must place the patient in a supine position to begin the postoperative. Here is no need to take the patient back to the unit.

The incision plays a major role. The posterolateral thoracotomies with section of the great muscles are painful; the wounds take longer to heal, causing varying degrees of immediate or late functional incompetence. When the incisions are performed early in life, they can cause major thoracic deformities. These problems are mostly reduced with a posterior incision and the preservation of the *latissimus dorsi* and *serratus anterior* muscles [13]. Therewith, we aim to reduce the surgical trauma as well as avoiding the use of electric scalpel in infants weighting less than 1800 g, what reduces the extent of tissue injury and do not depend on the adequate hospital equipment, and presents a lower raise of muscular enzyme in such a patient population who frequently have some degree of renal disorder.

An extra-pleural approach is adopted, whenever it is possible. However, the opening of the parietal pleura does not mean that the pleural drainage is mandatory. In some cases, when it is impossible to detach appropriately the parietal pleura from the thoracic wall, we prefer to open the parietal pleura widely, thus the risk of injury to the visceral pleura is minimized, improving the surgical field, what is very important to prevent iatrogenic injuries to occur, such as: ligation of the left branch of the pulmonary artery, ligation of the descending aorta, and injury to recurrent laryngeal nerve.

Recently, other surgical options have been described as minimally invasive. Vicent *et al.* [14] described a dorsal minithoracotomy in which the access is posterior, with the patient placed in a prone position. The ductus arteriosus is approached through the posterior mediastinum without opening the pleura. Srinivasan *et al.* [15] described both transaxillary and transpleural routes in 46 patients, age ranging from one month to 23 years. They reported less use

of thoracic drain (two cases). Mazzera et al. [16] reported an interesting option in which the access is obtained through the sternal furcula and the ductus is approached superiorly. The advantage of this route is to avoid a thoracotomy; however, the authors a small number of patients (five cases). Video-assisted thoracic surgery has been shown to be a safe and effective option of closing the patent ductus arteriosus, not only in children and adults, but in the preterm infants as well. Hines et al. [17] have been using this technique for a decade, including 100 performed on premature infants. They have demonstrated similar outcomes to the open routes without the evident benefit of using this method.

The obvious disadvantages are the high cost associated to the specialized material and to the strong necessity to proceed to the hospital surgical department. Leon-Wyss et al. [18] showed a similar experience in an ICU in Guatemala, in which, according to the authors, has limited resources. The same minimally invasive technique is used as in neonates as in school-age children (a total of 218 cases).

We emphatically advocate the use of metal "clips" to interrupt the ductus in premature infants. Besides being a faster and safer technique, it avoids the dissection and repair of the ductus, what reduces the risk of bleeding (in special in this population, where the coagulation disorders are often found by the prematurity or by the previous use of indomethacin) and injury to the recurrent laryngeal nerve [19].

However, there continues to be controversy as to the appropriate moment to indicate the surgery. The majority of the neonatal ICUs only perform the surgical technique after some attempts with the pharmacological treatment using indomethacin or ibuprofen. However, it seems to be a trend to indicate the surgical treatment earlier, with a low number of pharmacological attempts. Hines et al. [17] reported that the number of indomethacin courses prior to the surgical indication fell from 2.5, in 1996, to 1.76, in 2001. Despite of the fear to operate premature infants, it has been noted that the early indication should be beneficial. Jaillard et al. [20] reported that the surgical closure with less than three weeks of life improved the body growth and the likelihood of oral feeding when compared with late surgical closure.

Study limitations

Because it is a retrospective study, it is subjected to the data collection bias and it was not appropriately designed to compare surgical treatment versus clinical treatment. The revision of the medical records has pointed out error in five cases (13%), in which the cause of death was not clear or was inappropriately described as cardiorespiratory arrest.

CONCLUSION

The minimally invasive thoracotomy is a safe and effective technique for patent ductus arteriosus ligation in premature infants and excellent results have been reported. Because it does not depend on the local structure where the procedure is performed, it has great applicability. As this technique resolves faster the patients' ventilatory and circulatory disorders with low incidence of morbidity, should always be considered.

REFERENCES

1. Bell EF, Warburton D, Stonestreet BS, Oh W. Effect of fluid administration on the development of symptomatic patent ductus arteriosus and congestive heart failure in premature infants. *N Engl J Med.* 1980;302(11):598-604.
2. Siassi B, Blanco C, Cabal LA, Coran AG. Incidence and clinical features of patent ductus arteriosus in low-birthweight infants: a prospective analysis of 150 consecutively born infants. *Pediatrics.* 1976;57(3):347-51.
3. Way GL, Pierce JR, Wolfe RR, McGrath R, Wiggins J, Merenstein GB. ST depression suggesting subendocardial ischemia in neonates with respiratory distress syndrome and patent ductus arteriosus. *J Pediatr.* 1979;95(4):609-11.
4. Thibeault DW, Emmanouilides GC, Nelson RJ, Lachman RS, Rosengart RM, Oh W. Patent ductus arteriosus complicating the respiratory distress syndrome in preterm infants. *J Pediatr.* 1975;86(1):120-6.
5. Wyllie J. Treatment of patent ductus arteriosus. *Semin Neonatol.* 2003;8(6):425-32.
6. Cotton RB, Stahlman MT, Bender HW, Graham TP, Catterton WZ, Kovar I. Randomized trial of closure of symptomatic patent ductus arteriosus in small preterm infants. *J Pediatr.* 1978;93(4):647-51.
7. Friedman WF, Hirschklau MJ, Printz MP, Pitlick PT, Kirkpatrick SE. Pharmacologic closure of patent ductus arteriosus in the premature infant. *N Engl J Med.* 1976; 295(10):526-9.
8. Mahony L, Carnero V, Brett C, Heymann MA, Clyman RI. Prophylactic indomethacin therapy for patent ductus arteriosus in very-low-birth-weight infants. *N Engl J Med.* 1982;306(9):506-10.

9. Yeh TF, Luken JA, Thalji A, Raval D, Carr I, Pildes RS. Intravenous indomethacin therapy in premature infants with persistent ductus arteriosus: a double-blind controlled study. *J Pediatr*. 1981;98(1):137-45.
10. Ivey HH, Kattwinkel J, Park TS, Krovetz LJ. Failure of indomethacin to close persistent ductus arteriosus in infants weighing under 1000 grams. *Br Heart J*. 1979;41(3):304-7.
11. Meier MA, Jazbik W, Coutinho JH, Jazbik JC, Oliveira JA, Silva JC, et al. Manuseio do canal arterial patente no prematuro com síndrome de angústia respiratória: ligadura ou indometacina? *Rev Bras Cir Cardiovasc*. 1989;4(1):9-20.
12. McKee M. Operating on critically ill neonates: the OR or the NICU. *Semin Perinatol*. 2004;28(3):234-9.
13. Bethencourt DM, Holmes EC. Muscle-sparing posterolateral thoracotomy. *Ann Thorac Surg*. 1988;45(3):337-9.
14. Vicente WV, Rodrigues AJ, Ribeiro PJ, Evora PR, Menardi AC, Ferreira CA, et al. Dorsal minithoracotomy for ductus arteriosus clip closure in premature neonates. *Ann Thorac Surg*. 2004;77(3):1105-6.
15. Srinivasan B, Thingnam SK, Das D, Singh H. Approach to patent ductus arteriosus. *Ann Thorac Surg*. 2006;82(2):769.
16. Mazzera E, Brancaccio G, Feltri C, Michielon G, Di Donato R. Minimally invasive surgical closure of patent ductus arteriosus in premature infants: a novel approach. *J Card Surg*. 2002;17(4):292-4.
17. Hines MH, Raines KH, Payne RM, Covitz W, Cnota JF, Smith TE, et al. Video-assisted ductal ligation in premature infants. *Ann Thorac Surg*. 2003;76(5):1417-20.
18. Leon-Wyss J, Vida VL, Veras O, Vides I, Gaitan G, O'Connell M, et al. Modified extrapleural ligation of patent ductus arteriosus: a convenient surgical approach in a developing country. *Ann Thorac Surg*. 2005;79(2):632-5.
19. Mandhan PL, Samarakkody U, Brown S, Kukkady A, Maoate K, Blakelock R, et al. Comparison of suture ligation and clip application for the treatment of patent ductus arteriosus in preterm neonates. *J Thorac Cardiovasc Surg*. 2006;132(3):672-4.
20. Jaillard S, Larrue B, Rakza T, Magnenant E, Warembourg H, Storme L. Consequences of delayed surgical closure of patent ductus arteriosus in very premature infants. *Ann Thorac Surg*. 2006;81(1):231-4.