

# Mitral valve replacement with the preservation of the entire valve apparatus

*Substituição da valva mitral com preservação do aparato completo da valva*

Ahmed A. ALSADDIQUE<sup>1</sup>

RBCCV 44205-890

## Abstract

**Objective:** The papillary muscles and the chordae tendineae of both mitral leaflets contribute to the preservation of the left ventricular function. Most surgeons, however, routinely excise the anterior mitral leaflet.

**Methods:** In a group of nine patients, six of them underwent mitral valve replacement alone and three underwent both aortic and mitral valve replacements, all the mitral apparatus was preserved. All of these patients had mechanical valves using CarboMedics cardiac prosthesis (CarboMedics, Inc. Austin, Texas).

**Results:** There was no mortality. Postoperative echocardiographic assessment revealed maintained left ventricular function with no interference with the prosthetic

leaflet mobility and no left ventricular outflow tract gradient.

**Conclusion:** We believe that in most patients with long-standing mitral valve regurgitation, thinned out papillary muscles and elongated chordae tendineae that are not amenable to repair, valve replacement with the preservation of the entire native valve is possible and should be encouraged. This is especially valuable for those with depressed left ventricular function, who might otherwise suffer from left ventricular dysfunction in the long-term if the entire mitral valve apparatus were to be excised.

**Descriptors:** Mitral valve, surgery. Mitral valve insufficiency, surgery. Heart valve prosthesis implantation, methods.

1. Associate Professor of Surgery King Fahad Cardiac Center College of Medicine & King Khalid University Hospital

Work done at King Fahad Cardiac Center College of Medicine & King Khalid University Hospital, Saudi Arabia.

Correspondence address:

Ahmed A. Alsaddique, MD, FACS Associate Professor of Surgery Division of Cardiac Surgery College of Medicine & King Khalid University Hospital P.O.Box 7805. Riyadh, 11472 Saudi Arabia.

E-mail: alsadd@hotmail.com

Artigo recebido em 4 de novembro de 2006

Artigo aprovado em 18 de maio de 2007

### Resumo

**Objetivo:** Os músculos papilares e as cordas tendíneas de ambos folhetos mitral contribuem para a preservação da função ventricular esquerda. Muitos cirurgiões, entretanto, rotineiramente extirpar o folheto mitral anterior.

**Métodos:** Em um grupo de nove pacientes, seis deles foram submetidos à substituição da válvula mitral e três foram submetidos a substituições das válvulas mitral e aórtica, todos os aparatos mitraes foram preservados. Todos os pacientes tinham válvulas mecânicas implantadas usando próteses cardíacas CarboMedics (CarboMedics, Inc. Austin, Texas).

**Resultados:** Não houve mortalidade. A avaliação ecocardiográfica pós-operatória revelou a conservação da função ventricular esquerda sem interferência da mobilidade

protética do folheto e não tinha gradiente da via de saída do ventrículo esquerdo.

**Conclusão:** Acreditamos que, na maioria dos pacientes com regurgitação da válvula mitral crônica, uma redução no número dos músculos papilares e com as cordas tendíneas alongados que não favorecem os reparos, a substituição da válvula com a preservação inteira da válvula nativa é possível e deve ser encorajada. Isso é especialmente benéfico para aqueles pacientes com a função ventricular esquerda deprimida que podem, ao contrário sofrer de disfunção ventricular ao longo prazo se o aparato da válvula mitral fosse ser extirpada.

**Descritores:** Valva mitral, cirurgia. Insuficiência da valva mitral, cirurgia. Implante de prótese de valva, métodos.

## INTRODUCTION

The clinical improvement in patients who undergo mitral valve replacement for chronic mitral incompetence is related to an increase in cardiac output rather than improvement in left ventricular function [1]. On the other hand, in patients who undergo mitral valve repair for chronic mitral regurgitation, the left ventricular function appears to improve [2,3].

It would therefore appear from that observation that conventional mitral valve replacement (MVR) for chronic mitral regurgitation with prosthesis may be detrimental to the left ventricular function. With this information in mind, the value of preserving all of the mitral valve apparatus becomes apparent. There are many reports in the current literature that demonstrate the importance of retaining the subvalvular apparatus; as the integrity of the anterior and posterior leaflets and subvalvular apparatus contributes equally to left ventricular function preservation [4,5]. In addition, maintaining the papillary annular continuity has a proven advantage for left ventricular function [6,7].

## METHOD

This report is based on analysis of patients who underwent mitral valve replacement for chronic regurgitation, in whom the entire mitral valve apparatus was preserved, at the King Fahad Cardiac Center by one surgeon. After excluding patients who had coronary artery bypass along with mitral valve surgery, a total of nine patients had the preservation of the entire native valve and were available for analysis. Six of them underwent only mitral valve

replacement, all were females, and three underwent both aortic and mitral valve replacements, all were males. The average age was 35 years. All of these patients had rheumatic heart disease.

The diagnoses were confirmed echocardiographically in all patients. Cardiac catheterization was performed in only one patient, who was 65 years of age to rule out coronary artery disease. All of these patients, because of the chronicity of their disease, had depressed left ventricular function, and the average ejection fraction was 30%. The procedures are carried out through a median sternotomy, using moderate hypothermic cardiopulmonary bypass. The left atrium is opened after cross-clamping the aorta and induction of cardiac arrest by cold blood cardioplegia and topical ice slush for cooling.

The mitral valve is carefully inspected. The left atrial appendage is closed from within the left atrium. The potential for repair is thoroughly assessed, as it is always our first option. If the repair is ruled out then the anterior mitral leaflet is pulled out carefully to inspect it. An incision is then made few millimeters from the annulus along the anterior mitral ring as described by Miki et al. [8] (Figure 1). We have however added some modifications by incorporating the sutures to suspend the native valve into the prosthesis sewing ring. This decreases the bulk of tissue retained and therefore would help diminish the potential for interference with the prosthetic valve function.

The anterior leaflet is divided in the middle into anterior and posterior parts. The area in the middle is usually devoid of chordae and is excised in order to debulk the unnecessary tissue so that decent size prosthesis could be used (Figure 2). The anterior and posterior parts of the anterior leaflet are

re-attached to the mitral ring, near the anterolateral and posteromedial commissures, respectively, with 2-0 pledget-supported Ticon (Davis & Geck, Wayne NJ) sutures that are taken from the ventricular to the atrial side of the leaflet and slightly away from the free margin of the annulus (Figure 3). These sutures are left untied and are subsequently taken through the prosthetic valve ring along with the other valve sutures (Figure 4). The posterior leaflet is usually left as it is; on occasions it is incised in its middle vertically a few millimeters shy off the annulus so that proper size prosthesis can be used. When taking sutures in the posterior leaflet annulus the free edge of the leaflet should be included so that the leaflet is compressed between the prosthetic ring and the annulus and does not impinge on prosthesis causing it to malfunction.

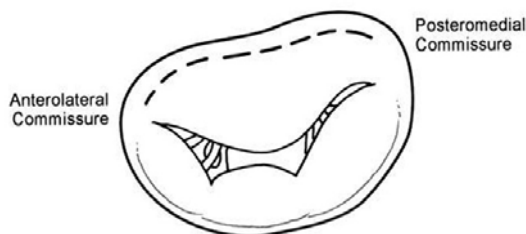

Fig. 1 - The mitral valve, dotted line is the area of incision in the anterior mitral leaflet

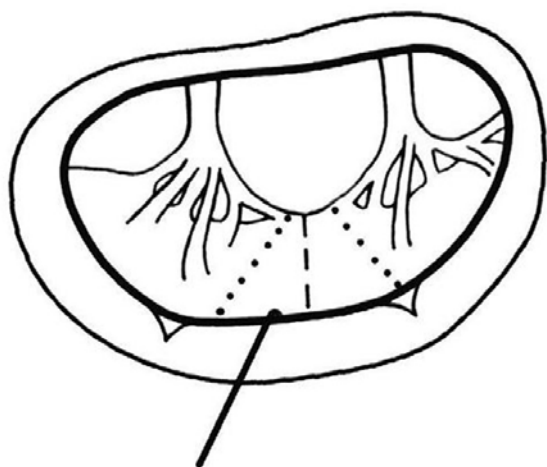


Fig. 2 - The anterior mitral leaflet is retracted by a hook. Chordae tendineae and papillary muscles of are shown. Dotted line is the chordae free portion to be excised

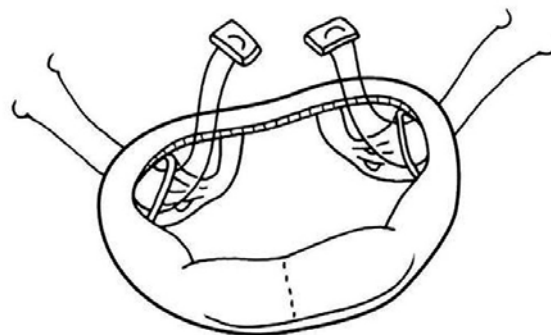


Fig. 3 - The anterior and posterior parts of the anterior leaflet are re-attached to the mitral ring near the anterolateral and posteromedial commissures

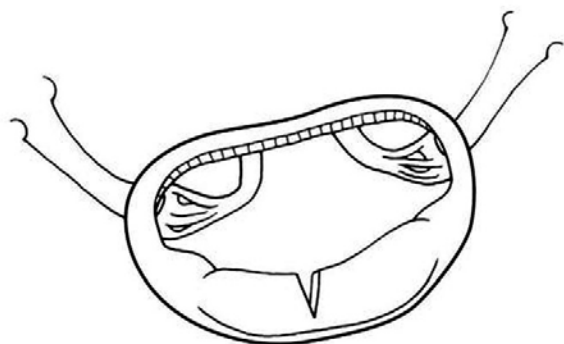


Fig. 4 - These sutures are left untied and are subsequently taken through the prosthetic valve ring along with the other valve sutures

The valve is sized and the implantation of the valves is carried out utilizing 2-0 pledget-supported Ticon (Davis & Geck, Wayne NJ) everting sutures. If the patient has both stenotic and incompetent lesions care should be taken in evaluating the feasibility of leaving the entire valvular apparatus behind. It is our experience that in such patients the mitral annulus is generally smaller than in pure chronic regurgitation and leaving the whole mitral apparatus behind may result in the utilization of a smaller prosthesis than desirable that could results in hemodynamic compromise.

Good judgment is called for in these situations. Orientation of the mitral valve is most commonly perpendicular to the anatomic position whereas the orientation of the aortic prosthesis is most commonly transverse with pivots at the midpoint of the non-coronary cusp and the commissure between the right and left cusps. Four patients received size 31 mm prosthesis and the rest were of size 29 mm one patient received a size 27 mm. The aortic valve sizes were 25 and 23 mm.

Echocardiograms were obtained in the preoperative assessments in the apical, parasternal, suprasternal and long axis projections. M-mode echocardiographic measurements of the left ventricular transverse dimensions were obtained with the ultrasound beam passing through the left ventricle just cephalad to the tip of the papillary muscles. Left ventricular end-diastolic dimension (LVDD) was measured at the R wave of a simultaneously recorded electrocardiogram, and end-systolic dimension (LVSD) was measured at the nadir of septal posterior systolic motion. The left ventricular ejection fraction was also assessed. All of these patients underwent echocardiography just before their discharge from the hospital and after six months in order to assess the left ventricular function and to assess the hemodynamics of the valves.

## RESULTS

All patients had the hemodynamic profile of chronic severe mitral regurgitation three had in addition severe aortic regurgitation. There was pulmonary hypertension, elevated pulmonary capillary wedge pressure, decreased cardiac index and elevated left ventricular end-diastolic pressure. There was left ventricular systolic and diastolic dilatation and contractile dysfunction.

The surgery was uneventful there was no operative mortality. The duration of cardiopulmonary bypass and cross clamp was comparable in the entire group. All the patients were easily weaned off cardiopulmonary bypass and maintained excellent hemodynamic parameters. The cardiac index became higher after surgery. The pulmonary capillary wedge pressure (PCWP) decreased significantly in comparison with the preoperative values. Cardiac index improved in all patients. Comparison between preoperative and postoperative hemodynamic variables is shown in Table 1.

Table 1. Hemodynamics variable comparison between preop and postop values

Hemodynamics	Preop	Postop	p Value
PCWP (mm Hg)	20 ± 5	13 ± 6	0.0081
PAMP (mm Hg)	30 ± 8	22 ± 6	0.0145
CI (L/min/m <sup>2</sup> )	2.1 ± 6	2.8 ± 0.9	0.035

PCWP: Pulmonary Capillary Wedge Pressure; PAMP: Pulmonary Artery Mean Pressure; CI: Cardiac Index.

Postoperative echocardiographic assessment is routinely done just before discharge to assess the ventricular and prosthetic valve functions and to rule the presence of significant pericardial effusion. It is repeated six weeks later and is compared with the perioperative findings. These studies revealed significant decrease in

LVDD and LVSD. There was in addition a significant reduction of the left atrial dimensions. The left ventricular ejection fractions were maintained without any deterioration. Echocardiographic parameters that were obtained six weeks after discharge are compared with the preoperative values in Table 2. There was no interference with the prosthetic leaflet mobility or left ventricular outflow tract gradient.

No instances of peri-valvular leak or intrinsic valvular dysfunction were observed.

Table 2. Echocardiographic parameters comparison between preop and postop data

Parameter	Preop	Postop	p Value
LA Dimension (mm)	64 ± 12	49 ± 10	0.0055
LVDD (mm)	73 ± 8	50 ± 7	0.0001
LVSD (mm)	50 ± 8	34 ± 6	0.0002
EF ( % )	31 ± 8	30 ± 5	NS

LA: Left Atrium; LVDD: Left Ventricular Diastolic Dimensions; LVSD: Left Ventricular Systolic Dimensions; EF: Ejection Fraction; NS: Not Significant.

## DISCUSSION

The attachment of the mitral valve and the left ventricular wall through the papillary muscles and chordae tendineae has a major role in the left ventricular function. The papillary muscles play an important role in left ventricular contraction by drawing the mitral ring towards the apex, thereby causing shortening of the axis for the ejection of blood [9]. In the early sixties, Lillehei et al. [11] capitalized on this fact and suggested that the high mortality rate associated with MVR could be reduced by retention of the papillary muscles and chordae tendineae. He preserved the posterior leaflet during mitral valve replacement and noted a decreased incidence of postoperative low cardiac output syndrome that used to plague early open-heart surgery. In addition, he also confirmed his prediction of a lower operative mortality in these patients [10]. The idea was greeted with skepticism by most of the prominent surgeons of his time and laid fallow for a long time. Around twenty years later, Hetzer et al. [11] became interested in Lillehei's technique utilizing tissue valve. This resurgence of interest was prompted because conventional MVR continued to be associated with a high prevalence of postoperative left ventricular dysfunction leading eventually to death. The most common cause of the late mortality is cardiac failure. Sporadic reports have since appeared in the literature describing the superior results of saving the entire valve apparatus. The crossed

papillopepy technique in mitral valve replacement also seeks to preserve mitral valve apparatus and thereby preserves left ventricular function. On follow up it was found to lead to improvement of ventricular remodeling [12].

Once surgeons realized the importance of the mitral valve apparatus new innovative techniques have emerged to preserve it. Puig et al. [13] described a method in which both the anterior and posterior leaflets of the mitral valve were divided into hemileaflets. The resultant four pedicles were displaced under traction toward the left atrium and anchored between the mitral annulus and an implanted valvular prosthesis. What is interesting in the technique is that post operative Doppler echocardiography revealed evidence of LV remodeling in some of these patients, including lateral wall changes and a tendency of the LV cavity to return to its elliptical shape. The contribution of the Restore group [14] again reflects the importance of preserving the subvalvular apparatus. They described a new surgical approach in patients with end-stage cardiomyopathy and severe mitral regurgitation who otherwise would be candidates for cardiac transplantation. It consists of implantation of a mitral prosthesis that is smaller than the annulus, and preservation and traction of the papillary muscles to reduce sphericity of the left ventricle [14]. The mid-term follow up revealed a relatively flat late survival curve, with evidence of improved clinical status, better echocardiographic parameters and reduction in ventricular sphericity.

The importance of preservation of the native valve and the attached chordae has eventually gained popularity. Chordal preservation appears to represent a significant departure from the trend of worsening results after conventional MVR [15], yet analogous to results associated with mitral reconstruction [16,17]. Nevertheless retention of the posterior leaflet with anterior leaflet resection is the more customary method of MVR this is probably for fear of left ventricular outflow obstruction by papillary muscles and chordae tendineae of the anterior leaflet [18] as is described in some isolated case reports. This has not been the experience of most [19,20] and indeed not ours. Chordal preservation during MVR for severe mitral regurgitation preserves left ventricular ejection fraction results in reduction of both LVSD and LVDD and improves the cardiac index. Mitral valve's apparatus preservation should be the procedure of choice in patients who require MVR for mitral regurgitation when mitral repair is not possible as repair should always be the first choice in any mitral procedure.

## REFERENCES

1. Morton MJ, Bohnsted SW, Pantely GA, Rahmitoola S. Effect of successful mitral valve replacement on left ventricular function. *Circulation*. 1980;62(suppl III):III-208.
2. Duran CG, Pomar JL, Revuelta JM, Gallo I, Poveda J, Ochoteco A, et al. Conservative operation for mitral insufficiency: critical analysis supported by postoperative hemodynamic studies in 72 patients. *J Thorac Cardiovasc Surg*. 1980;79(3):326-37.
3. Braunberger E, Deloche A, Berrebi A, Abdallah F, Celestin JA, Meimoun P, et al. Very long-term results (more than 20 years) of valve repair with Carpentier's techniques in nonrheumatic mitral valve insufficiency. *Circulation*. 2001;104(12 Suppl 1):I8-11.
4. Okita Y, Miki S, Ueda Y, Tahata T, Sakai T, Matsuyama K. Mitral valve replacement with maintenance of mitral annulopapillary muscle continuity in patients with mitral stenosis. *J Thorac Cardiovasc Surg*. 1994;108(1):42-51.
5. Okita Y, Miki S, Ueda Y, Tahata T, Sakai T. Left ventricular function after mitral valve replacement with or without chordal preservation. *J Heart Valve Dis*. 1995;4(Suppl 2):S181-93.
6. Solomon NA, Pranav SK, Naik D, Sukumaran S. Importance of preservation of chordal apparatus in mitral valve replacement. *Expert Rev Cardiovasc Ther*. 2006;4(2):253-61.
7. Gams E, Schad H, Heimisch W, Hagl S, Mendler N, Sebening F. Preservation versus severance of the subvalvular apparatus in mitral valve replacement: an experimental study. *Eur J Cardiothorac Surg*. 1990;4(5):250-5.
8. Miki S, Kusuhara K, Ueda Y, Komeda M, Ohkita Y, Tahata T. Mitral valve replacement with preservation of chordae tendineae and papillary muscles. *Ann Thorac Surg*. 1988;45(1):28-34.
9. Solomon NA, Pranav SK, Naik D, Sukumaran S. Importance of preservation of chordal apparatus in mitral valve replacement. *Expert Rev Cardiovasc Ther*. 2006;4(2):253-61.
10. Lillehei CW, Levy MJ, Bonabeau RC Jr. Mitral valve replacement with preservation of papillary muscles and chordae tendineae. *J Thorac Cardiovasc Surg*. 1964;47:532-43.
11. Hetzer R, Bougioukas G, Franz M, Borst HG. Mitral valve replacement with preservation of papillary muscles and chordae tendineae: revival of a seemingly forgotten concept: I Preliminary clinical report. *Thorac Cardiovasc Surg*. 1983;31(5):291-6.
12. Gomes OM, Gomes ES, Santana Filho GP. New technical approach for crossed papillopepy in mitral valve replacement surgery: short term results. *Braz J Cardiovasc Surg*. 2005;20(3):340-5.
13. Puig LB, Gaiotto FA, Oliveira JL Jr, Pardi MM, Bacal F, Mady C, et al. Mitral valve replacement and remodeling of the left ventricle in dilated cardiomyopathy with mitral regurgitation: initial results. *Arq Bras Cardiol*. 2002;78(2):224-9.

- 
14. Buffolo E, Branco JN, Catani R; RESTORE Group. End-stage cardiomyopathy and secondary mitral insufficiency surgical alternative with prosthesis implant and left ventricular restoration. *Eur J Cardiothorac Surg*. 2006;29(Suppl 1):S266-71.
  15. Ferrazzi P, McGiffin DC, Kirklin JW, Blackstone EH, Bourge RC. Have the results of mitral valve replacement improved? *J Thorac Cardiovasc Surg*. 1986;92(2):186-97.
  16. Okada Y, Nasu M, Takahashi Y, Handa N, Fujiwara H, Shinkai M, et al. Late results of mitral valve repair for mitral regurgitation. *Jpn J Thorac Cardiovasc Surg*. 2003;51(7):282-8.
  17. Moss RR, Humphries KH, Gao M, Thompson CR, Abel JG, Fradet G, et al. Outcome of mitral valve repair or replacement: a comparison by propensity score analysis. *Circulation*. 2003;108(Suppl 1):II90-7.
  18. Come PC, Riley MF, Weintraub RM, Wei JY, Markis JE, Lorell BH, et al. Dynamic left ventricular outflow tract obstruction when the anterior leaflet is retained at prosthetic mitral valve replacement. *Ann Thorac Surg*. 1987;43(5):561-3.
  19. Vander Salm TJ, Papa LA, Mauser JF. Mitral valve replacement with complete retention of native leaflets. *Ann Thorac Surg*. 1995;59(1):52-5.
  20. Aagaard J, Andersen UL, Lerbjerg G, Andersen LI. Expanding the use of total mitral valve preservation in combination with implantation of the CarboMedics heart valve prosthesis. *J Cardiovasc Surg (Torino)*. 1999;40(2):177-81.